

# Nasal septal perforation in systemic lupus erythematosus

Joe Thomas<sup>1</sup> , Praveen Gopinath<sup>2</sup> 

A 40-year-old female with systemic lupus erythematosus was admitted with typical characteristics of active lupus in the form of palatal ulcers, alopecia, bicytopenia, lupus nephritis (class 4), necrotizing lymphadenopathy, high-titer anti-double-stranded deoxyribonucleic acid, and low complements. P-ANCA and C-ANCA tests performed using ELISA method were negative. Otorhinolaryngology opinion was taken for nasal block, and a diagnostic nasal endoscopy showed a large septal perforation involving the anteroinferior and anterosuperior parts of the cartilaginous nasal septum with severe crusting over the edges of the septal perforation. The crusts were endoscopically cleared, edges of the perforation were smeared with an antibiotic cream, and the patient started the use of saline nasal douches. She was treated with pulse methylprednisolone, mycophenolate mofetil, hydroxychloroquine, and other supportive medications. The patient attained remission over time, and periodic endoscopic examination showed the perforation to be stable in size and free of major crusting (Figure 1). Nasal septal perforation is an underdiagnosed complication of lupus because it is asymptomatic and the patients are often not aware of their nasal problem (1). Nasal septal perforation in lupus may be secondary to vasculitis or to ischemia with subsequent chondrolysis (2). Treatment should primarily be directed to control disease activity.

#### ORCID IDs of the authors:

J.T. 0000-0001-7255-6356;  
P.G. 0000-0003-2361-7575.

**Cite this article as:** Thomas J, Gopinath P. Nasal septal perforation in systemic lupus erythematosus. *Eur J Rheumatol* 2019; 6(3): 161-2.

<sup>1</sup> Department of Orthopaedics & Rheumatology, Aster Medcity, Kerala, India

<sup>2</sup> Department of Otorhinolaryngology, Aster Medcity, Kerala, India

#### Address for Correspondence:

Joe Thomas, Department of Orthopaedics & Rheumatology, Aster Medcity, Kerala, India

E-mail: joethomasmd@yahoo.co.in

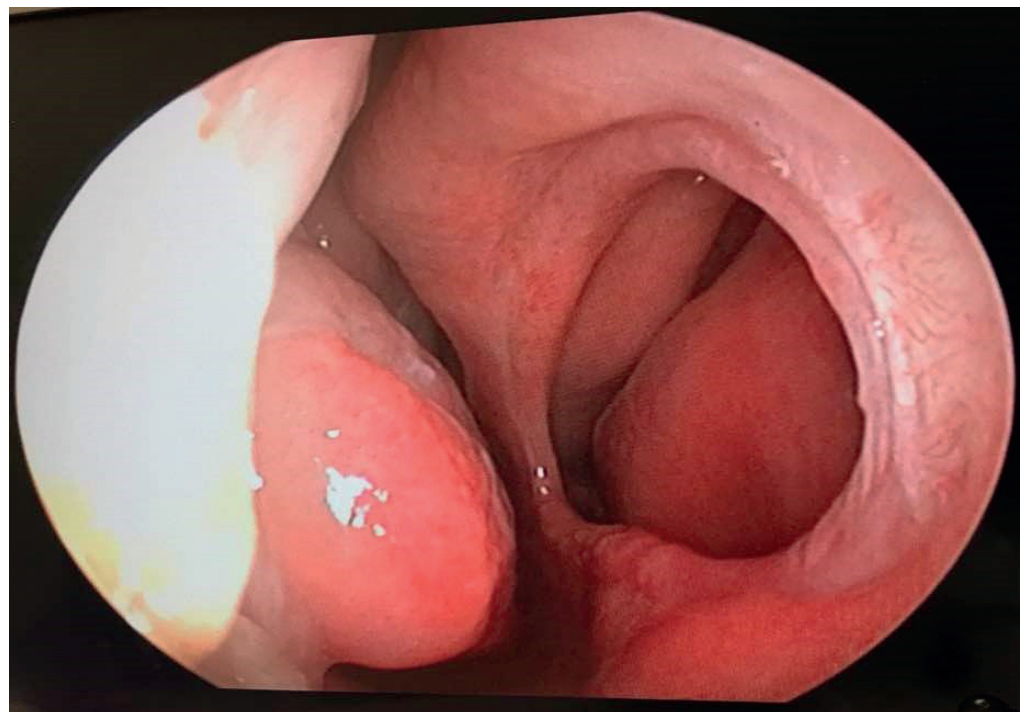
Submitted: 10 July 2018

Accepted: 5 October 2018

Available Online Date: 19 December 2018

Copyright © Author(s) - Available online at [www.eurjrheumatol.org](http://www.eurjrheumatol.org)

Content of this journal is licensed under a Creative Commons Attribution-NonCommercial 4.0 International License.



**Figure 1.** Large septal perforation involving the anteroinferior and anterosuperior parts of the cartilaginous nasal septum

**Informed Consent:** Written informed consent was obtained from patient who participated in this study.

**Peer-review:** Externally peer-reviewed.

**Author Contributions:** Concept - J.T., P.G.; Design - J.T., P.G.; Supervision - J.T., P.G.; Data Collection and Processing - J.T., P.G.; Analysis and/or Interpretation - J.T.,

P.G.; Literature Search - J.T., P.G.; Writing Manuscript - J.T., P.G.; Critical Review - J.T., P.G.

**Conflict of Interest:** The authors have no conflict of interest to declare.

**Financial Disclosure:** The authors declared that this study has received no financial support.

## References

1. Reiter D., Myers A.R. Asymptomatic nasal septum perforation in Systemic Lupus Erythematosus. *Ann Otol* 1980; 89: 78-80.
2. Rahmam P, Gladman D, Urowitz M. Nasal septum perforation in Systemic Lupus Erythematosus - Time for a closer look. *J Rheumatol* 1999; 26: 1854-5.