

Prominent tenosynovitis on ultrasonography: A useful sign for the diagnosis of Blau syndrome

Aaqib Zaffar Banday , Swetlana Mukherjee , Rajni Kumrah , Deepti Suri , Ankur Kumar Jindal 

A 28-month-old boy presented with a history of recurrent fever, pain, and swellings over the dorsal aspect of the wrist and ankle joints since the age of 8 months. His mother and maternal grandmother had had similar complaints since early childhood. On examination, it was found that he had boggy swellings over the extensor aspect of the ankle and wrist joints (Figure 1a and b) and also had a non-erythematous micropapular rash, which was most prominent over the extensor aspect of the forearms and hands (Figure 1). Laboratory investigations showed thrombocytosis (platelet count [$\times 10^9/L$]: 542 [normal 150-400]) and high C-reactive protein (8.53 mg/L [normal <6]). Slit-lamp examination showed no uveitis. Ultrasonography showed marked tenosynovitis of the extensor tendons overlying the wrist and ankle joints (Figure 1c-e). A clinical possibility of Blau syndrome (BS) was considered. Sanger sequencing showed p.R334W mutation in *NOD2/CARD15* gene. He was initiated on subcutaneous methotrexate and remained well on follow-up. The mother of the index child was subsequently diagnosed (for the first time) with BS and had the same genetic defect.

BS is a rare autoinflammatory autosomal dominant disorder that presents in early childhood with a classic triad of rash, arthritis, and uveitis. However, as this triad may not be obvious in all patients, there can be inadvertent delays in diagnosis.¹ Arthritis in BS is characterized by boggy joint swellings as seen in the case studied by us. The presence of prominent tenosynovitis around affected joints is a characteristic ultrasonography sign.² Besides, musculoskeletal ultrasonography has been suggested to be a useful disease monitoring tool in patients with BS.³

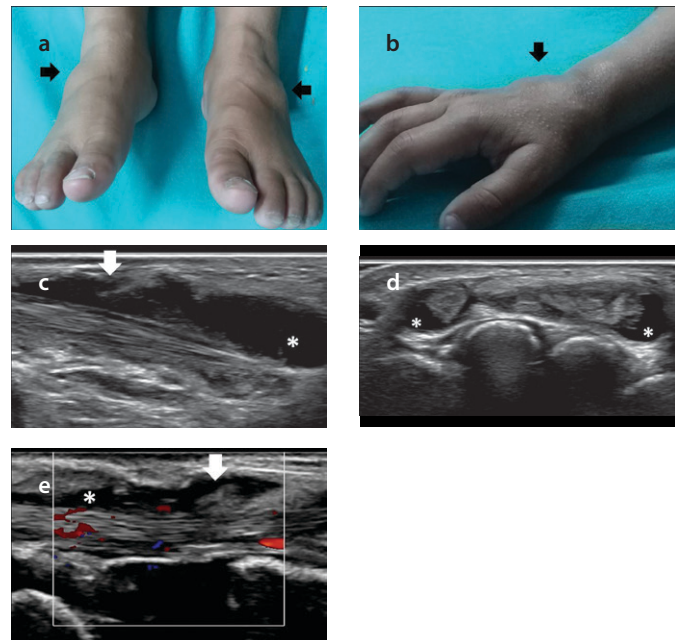


Figure 1. a-e. Clinical photographs and ultrasound images in a child with Blau syndrome. Boggy swellings (black arrows) over the ankle joints (a). Boggy swelling (black arrow) and micropapular rash over the dorsum of the right hand and wrist (b). Gray-scale synovitis of the tibialis anterior tendon (dorsal medial longitudinal scan) (c). Gray-scale synovitis of the extensor tendons of hand (dorsal transverse scan) (d). Gray-scale synovitis of one of the extensor digitorum tendons (dorsal longitudinal scan), with color Doppler reflecting increased blood flow (indicative of inflammation) (e). White arrows: synovial proliferation (hypoechoic frond-like projections); Asterisks: abnormal fluid accumulation (anechoic areas) (c-e).

ORCID iDs of the authors:

A.Z.B. 0000-0001-5486-4267;
S.M. 0000-0002-8959-9691;
R.K. 0000-0001-5034-2007;
D.S. 0000-0001-5009-8761;
A.K.J. 0000-0002-7954-0661.

Cite this article as: Banday AZ, Mukherjee S, Kumrah R, Suri D, Jindal AK. Prominent tenosynovitis on ultrasonography: A useful sign for the diagnosis of Blau syndrome. *Eur J Rheumatol* 9 February 2021;9(1):58-59.

Unit of Allergy Immunology, Department of Pediatrics, Advanced Pediatrics Centre, Post Graduate Institute of Medical Education and Research (PGIMER), Chandigarh, India

Address for Correspondence:

Ankur Kumar Jindal; Unit of Allergy Immunology, Department of Pediatrics, Advanced Pediatrics Centre, Post Graduate Institute of Medical Education and Research (PGIMER), Chandigarh, India

E-mail: ankurjindal11@gmail.com

Submitted: September 01, 2020

Accepted: October 23, 2020

Available Online Date: February 9, 2021

Copyright@Author(s) - Available online at www.eurjrheumatol.org.

Content of this journal is licensed under a Creative Commons Attribution-NonCommercial 4.0 International License.



evaluation for BS in patients labeled as having JIA. However, the sensitivity (and specificity) of this approach is largely unknown owing to the paucity of data.

In addition, patients have been reported to receive multiple other diagnoses, including refractory uveitis, vasculitis, tuberculosis, and systemic lupus erythematosus, before the final diagnosis of BS was confirmed.⁴ These patients may have subclinical tenosynovitis that can be picked up by ultrasonography and help clinch the correct diagnosis of BS. Tenosynovitis on ultrasonography, although reported in the literature in the context of BS, remains an under-utilized sign that may serve as a useful clue for diagnosing BS, especially in the absence of the characteristic triad of clinical manifestations.

Written informed consent was obtained from the patients.

Informed Consent: Written informed consent was obtained from the patients.

Peer-review: Externally peer-reviewed.

Author Contributions: Concept - A.Z.B., S.M., R.K., D.S., A.K.J.; Design - A.Z.B., S.M., R.K., D.S., A.K.J.; Supervision - D.S., A.K.J.; Materials - D.S., A.K.J.; Data Collection and/or Processing - A.Z.B., S.M., R.K., D.S., A.K.J.; Analysis and/or Interpretation - A.Z.B., S.M., R.K., A.K.J.; Literature Search - A.Z.B., S.M., R.K.; Writing Manuscript - A.Z.B., S.M., R.K., D.S., A.K.J.; Critical Review - A.Z.B., S.M., R.K., D.S., A.K.J.

Conflict of Interest: The authors have no conflict of interest to declare.

Financial Disclosure: The authors declared that this study has received no financial support.

References

1. Jindal AK, Pilonia RK, Suri D, et al. A young female with early onset arthritis, uveitis, hepatic, and renal granulomas: A clinical tryst with Blau syndrome over 20 years and case-based review. *Rheumatol Int.* 2019 May 6. doi: 10.1007/s00296-019-04316-6. [Epub ahead of print]. [\[Crossref\]](#)
2. Ikeda K, Kambe N, Satoh T, et al. Preferentially inflamed tendon sheaths in the swollen but not tender joints in a 5-year-old boy with Blau syndrome. *J Pediatr.* 2003;163:1525.e1. [\[Crossref\]](#)
3. Ikeda K, Kambe N, Takei S, et al. Ultrasonographic assessment reveals detailed distribution of synovial inflammation in Blau syndrome. *Arthritis Res Ther.* 2014;16:R89. [\[Crossref\]](#)
4. Matsuda T, Kambe N, Ueki Y, et al. Clinical characteristics and treatment of 50 cases of Blau syndrome in Japan confirmed by genetic analysis of the NOD2 mutation. *Ann Rheum Dis.* 2020;79:1492-1499. [\[Crossref\]](#)