

Syringomyelia presenting as neuropathic arthropathy of basal and shoulder joints

Ganesh Singh Dharmshaktu 

A 45-year-old right-hand-dominant male shopkeeper presented with stiffness of the left thumb base and clumsiness during work for the last 5 months. He also had a long history of undergoing physiotherapy for stiffness of the ipsilateral shoulder for the last 2 years. There was also a history of intermittent paresthesia and weakness in the left upper extremity since 5 years, but, recently, the stiffness had increased markedly. No history of injury, chronic diseases, and other forms of arthritis, such as rheumatoid or seronegative arthropathy, were present in the patient and family. There was no history of diabetes, hypertension, tuberculosis, gastrointestinal, urogenital, or any other neurological disorders. The patient had little impact on his vocation.

The higher intellectual function evaluation and neurological examination was normal for contralateral upper and both lower extremities.

Left thumb base had visible swelling and deformity, as compared with the opposite side (Figure 1). Subluxation and instability at first carpometacarpal (CMC) or basal joint were noted along with terminal restriction of movement on examination. The range of motion of his left shoulder, though painless, was limited to 25°, with a flexion of 50° and abduction of 60°, without any swelling, tenderness, or local raised temperature. Decrease in pain, fine touch, and temperature sensation was noted in the left side with intact proprioception. The radiographs showed joint destruction and narrowing in left thumb trapezometacarpal or CMC joint (Figure 2a). There was severe destruction of left glenohumeral and acromioclavicular joints along with osteophytes formation (Figure 2b). The magnetic resonance imaging (MRI) of cervical spine revealed presence of a central syrinx in cervical and upper dorsal cord. Spinal cord compression at cranio-vertebral junction and associated tonsillar herniation (Figure 3). Diagnosis of secondary neuropathic arthropathy of shoulder and basal joint in the setting of syringomyelia was made and the patient was managed with physiotherapy, splints, and ergonomic changes to reduce joint loading. He was later referred to the advanced neurosurgery center for expert spinal management.

Neuropathic arthropathy or Charcot joint is a disabling clinical condition resulting from various causes, such as diabetes, syphilis, cerebral palsy, and spinal cord injury or its malformations. Joint destruction following an abnormal sensory ability results in aberrant response to stress and osteoclastic activity leading to varying grades of arthritis or deformities.¹ Usually large joints and, thus, weight bearing are affected with this condition, and cervical spine syringomyelia is an uncommon cause of neuropathic arthropathy. The syringomyelia caused by basilar impression leading to



Figure 1. The clinical image of the left hand showing the swollen base of thumb and deformity (shown by arrow).

ORCID iD of the author:
G.S.D. 0000-0002-8063-4622.

Cite this article as: Dharmshaktu GS. Syringomyelia presenting as neuropathic arthropathy of basal and shoulder joints. *Eur J Rheumatol.* 2021;8(4):235-236.

Department of Orthopaedics,
Government Medical College, Haldwani,
Uttarakhand, India

Address for Correspondence:

Ganesh Singh Dharmshaktu; Department
of Orthopaedics, Government Medical
College, Haldwani, Uttarakhand, India

E-mail: drganeshortho@gmail.com

Submitted: July 13, 2020

Accepted: August 22, 2020

Available Online Date: November 11, 2020

Copyright©Author(s) - Available online at
www.eurjrheumatol.org.

Content of this journal is licensed under a Creative
Commons Attribution-NonCommercial 4.0
International License.



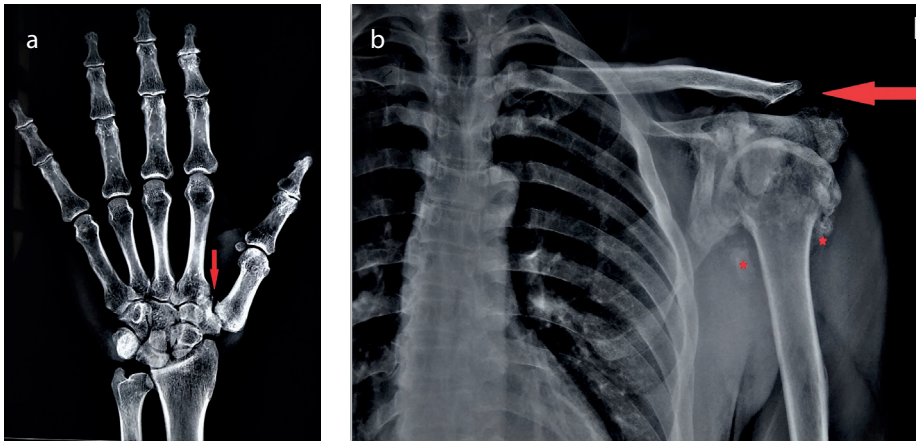


Figure 2. a, b. The anteroposterior hand radiograph showing first carpo-metacarpal joint (basal joint) arthritis and deformity (denoted by arrow) (a). The shoulder joint radiograph showing deformed anatomy of articulating bones of glenohumeral with decreased joint space and extensive osteophytes (denoted by stars) suggesting secondary arthritis; the acromioclavicular joints are almost non-existent due to severe resorption (b).

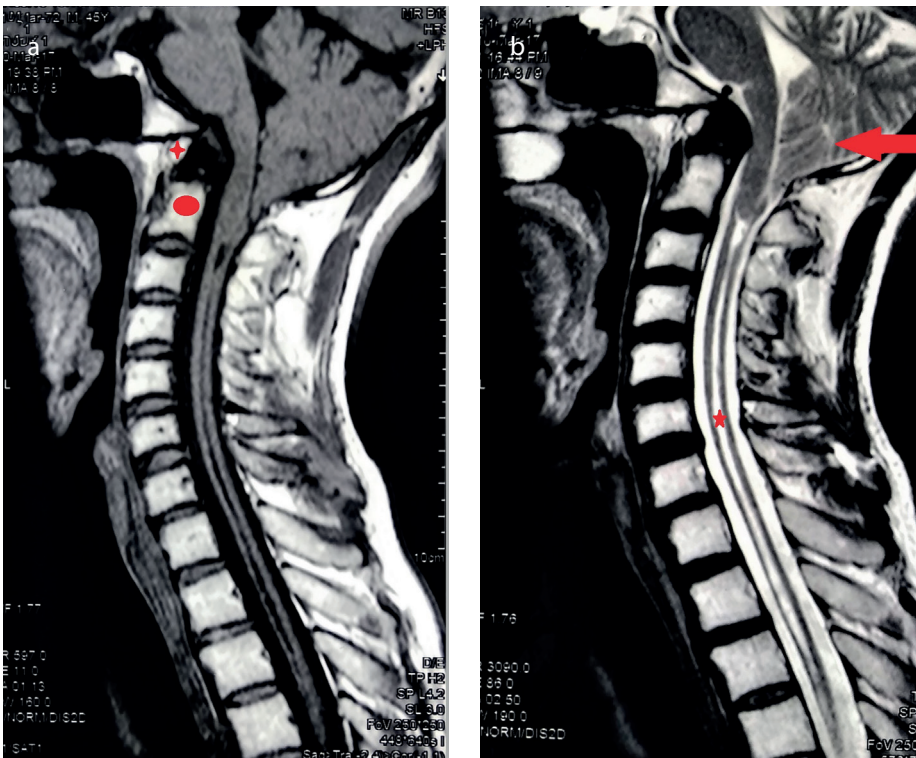


Figure 3. a, b. Sagittal T1 (a) and T2 (b) weighted images show hyperintense signals within cervical and upper dorsal cord in T1 and hypointense ones in T2 views (denoted by star), suggesting syrinx formation. Atlantoaxial dislocation is evident by the anatomical mismatch between atlas (denoted by red oval shape) and hypoplastic dens (denoted by four-pointed star). Cerebellar tonsillar herniation beyond foramen magnum (denoted by arrow) is also noted.

Charcot arthropathy of the shoulder is a rare event.² Shoulder joint is involved in only 6% cases with syringomyelia whereas hand joints are rarely involved.³ Wrist and metacarpophalangeal joints with oligoarthritic presentation have been reported in one study.⁴ Isolated unilateral basal joint involvement is rare with only one previous case of ipsilateral shoulder and thumb CMC joint involvement along with cervical syringomyelia being reported.⁵ Consensus on treatment of neuropathic arthropathy is not clear and requires robust studies. Atypical small-joint arthropathy should warrant exclusion of spinal malformation as an associated condition.

Written informed consent was taken from the patient.

Informed Consent: Written informed consent was obtained from the patient.

Peer-review: Externally peer-reviewed.

Conflict of Interest: The author has no conflict of interest to declare.

Financial Disclosure: The author declared that this study has received no financial support.

References

1. Yanik B, Tuncer S, Seckin B. Neuropathic arthropathy caused by arnold-chiari malformation with syringomyelia. *Rheumatol Int.* 2004;24:238-241. [\[Crossref\]](#)
2. Wang X, Li Y, Gao J, et al. Charcot arthropathy of the shoulder as a presenting feature of basilar impression with syringomyelia: A case report and literature review. *Medicine (Baltimore).* 2018;97:e11391. [\[Crossref\]](#)
3. Nambiar M, Onggo RJ, Pai V. Neuropathic arthropathy of the shoulder joint secondary to a syringomyelia. *BMJ Case Rep.* 2018;11:bcr-2018-228228. [\[Crossref\]](#)
4. Groseanu L, Heretiu L, Gudu T, et al. Neuropathic arthropathy of the hand associated with cervical syringomyelia. *Romanian J Rheumatol.* 2015;24:50-54. [\[Crossref\]](#)
5. Butala RR, Arora M, Rao AA, et al. A rare case of ipsilateral shoulder and thumb CMC joint neuropathic arthropathy. *J Surg Case Rep.* 2014;2014:rju054. [\[Crossref\]](#)