

Successful treatment of pediatric Tolosa-Hunt syndrome with adalimumab

Jameson Wiener , Randy Q. Cron 

Abstract

Objective: Tolosa-Hunt syndrome (THS) is a rare disease characterized by painful unilateral ophthalmoplegia and headache. THS is caused by granulomatous inflammation of the cavernous sinus, and its diagnosis is typically made by elimination and exclusion. The characteristic pain can typically be managed with steroid therapy, but relapses are common. Additional therapy is needed for refractory or recurrent cases.

Methods: Herein, using the electronic medical record with institutional review board approval, we report a case of a pediatric patient diagnosed with corticosteroid-dependent THS. The child was effectively treated with the tumor necrosis factor inhibitor (TNFi), adalimumab. We have reviewed the THS literature, including 2 adult THS patients who have been successfully treated with intravenous TNFi, infliximab.

Results: This is the first report in the scientific literature to effectively treat pediatric THS, and also the first such case to use adalimumab to successfully treat THS.

Conclusion: Adalimumab, a subcutaneous TNFi, appears to be an effective treatment for corticosteroid-dependent THS.

Keywords: Tolosa-Hunt syndrome, ophthalmoplegia, pediatric, adalimumab, tumor necrosis factor, monoclonal antibody

Introduction

Tolosa-Hunt syndrome (THS) was first described in 1961 by Hunt et al. (1) It is caused by granulomatous inflammation of the cavernous sinus or the superior orbital fissure. The annual estimated incidence of THS is rare and has been reported as approximately 1 case per million people each year. It is even more unusual to encounter THS in pediatric populations (2, 3). The syndrome is characterized by painful ophthalmoplegia with periorbital or hemicranial pain and can also present with ipsilateral ocular motor nerve palsies, oculomotor paralysis, and sensory loss in the distribution of the ophthalmic or maxillary division of the trigeminal nerve (3, 4). The criteria for diagnosis as per the International Headache Society (IHS) (3, 5) is typically used for diagnosing this condition. Here we present a case of THS in a pediatric patient that was successfully treated with adalimumab. To our knowledge, there have been no published cases of the use of adalimumab as a therapy for THS in the literature to date.

Case Presentation

An 8-year-old Caucasian female presented to the emergency department with a complaint of severe right eye pain for one month, right-sided headache for three weeks, and a one week history of blurry/double vision and right jaw pain. On admission, her clinical examination was notable for severe cranial nerve VI and VII (CN VI/CN VII) palsy with diplopia on ipsilateral gaze, severe headache, and photophobia. Lumbar puncture was performed, and cerebrospinal fluid (CSF) showed elevated white blood cells with 78% lymphocytes. MRI (Figure 1A) with and without contrast with fat suppression of the orbits was compatible with a diagnosis of THS with thickening of the right cavernous sinus and a small right internal carotid artery, and abnormal enhancement of both cavernous sinuses. C-reactive protein, erythrocyte sedimentation rate, renal function panel, antinuclear antibody, and antineutrophil cytoplasmic antibody assays were within normal limits. Tuberculosis (TB) purified protein derivative (PPD) test was negative. A brain biopsy was discussed with the patient's family to confirm the diagnosis, however, the family declined at the time due to the high-risk nature of the surgery. The patient was started on a 3-day burst of high-dose steroids (1 gm methylprednisolone), which resulted in significant improvement in her pain. The patient was transitioned to prednisone 40 mg and discharged after a 4-day hospital stay with instructions to follow-up with

ORCID IDs of the authors:

J.W. 0000-0002-8808-2535;
R.Q.C. 0000-0003-2661-3086.

Cite this article as: Wiener J, Cron RQ.
Successful treatment of pediatric Tolosa-Hunt syndrome with adalimumab. Eur J Rheumatol 2020; 7(Suppl 1): S82-S84.

Department of Pediatrics, University of Alabama, Birmingham, Alabama, USA

Address for Correspondence:
Randy Cron; Department of Pediatrics,
University of Alabama, Birmingham,
Alabama, USA

E-mail: rcron@peds.uab.edu

Submitted: July 31, 2019

Accepted: September 14, 2019

Available Online Date: December 3, 2019

Copyright©Author(s) - Available online at
www.eurjrheumatol.org.

Content of this journal is licensed under a Creative Commons Attribution-NonCommercial 4.0 International License.



the rheumatology department and undergo patching of the right eye for management of the patient's diplopia.

Three days later, the patient was readmitted to the hospital for worsening pain located posterior to the right ear and along her right jaw. Her CN VI and VII palsies were unchanged. The family reported her compliance with the prednisone treatment and a several pound gain in weight since discharge. A repeat MRI showed persistent dural thickening of the middle cranial fossa, a cavernous sinus lesion, and subtle enhancement along the right facial nerve and internal auditory canal. An infectious disease workup was commenced, and empiric treatment for TB basilar meningitis was started. Human immunodeficiency virus, Rocky Mountain spotted fever, Bartonella, and rapid plasma reagin were all found to be negative. The neurosurgery department was consulted and the patient was subjected to craniotomy with a dural biopsy.

The biopsy sample showed dural patchy chronic inflammation with one focus of granuloma formation. Furthermore, rare mycobacteria were present. Additional TB workup was initiated, including gastric samples. The patient was discharged on pyridoxine, ethionamide, isoniazid, pyrazinamide, and prednisone. The TB workup, including PPD, chest radiograph, blood T-spot testing, polymerase chain reaction (PCR), CSF culture, TB PCR, sputum PCR with stain and culture, gastric fluid PCR with stain and cultures all returned as negative.

Nine months following her initial presentation, the patient was continuing with steroid therapy and her exam was unchanged from the previous hospitalization. As the diagnosis was still unclear, and out of concern that her symptoms may be secondary to lymphoma or another new neoplastic process, a repeat biopsy was planned.

Biopsy specimen of the right cavernous sinus dura demonstrated patchy chronic inflammation composed of lymphocytes (predominantly reactive T-cells) and macrophages (confirmed with immunostaining). Biopsy showed no definitive evidence of neoplasia, granulomas, fungi, or mycobacterium. The patient was discharged with continued steroid therapy and close outpatient follow-up after recovery from surgery.

Approximately 1 month later, the patient presented with worsening headache and concern for new-onset left CN VI palsy concerning for THS versus hypertrophic pachymeningitis. By this time, the patient had been examined by the rheumatology, neurology, infectious disease, neuro-ophthalmology, hematology/oncology, and palliative care departments. THS is a diagnosis of exclusion, however, given the patient's already extensive workup, and concern for worsening disease despite therapy with steroids, the decision to treat with steroids and steroid-sparing immunosuppressive therapy was made. The patient completed a 3-day course of pulse dose steroid (IV methylprednisolone) and was started on methotrexate (20 mg subcutaneously every week) and adalimumab several days later (40 mg every other week) to reduce the underlying inflammatory process. The patient was discharged on prednisone with the goal of tapering during follow-up appointments with the rheumatology and neurology departments.

Six months later, at the rheumatology follow-up, the patient's family endorsed improved headache frequency and intensity. They communicated that there had been minimal side effects with the most recently implemented treatment regimen. Repeat imaging showed

resolution of cavernous sinus thickening and an unremarkable MRI (Figure 1B).

Five months after this appointment, the patient's family reported that there had been a confusion with the pharmacy, and the patient had not received four doses of methotrexate leading up to the appointment. She continued to receive her adalimumab as scheduled. On adalimumab alone, the patient had dramatically improved. Now 11 years old, she complained of an occasional headache but the stated headache severity and duration had improved greatly as compared to the previous years. Her CN VI and VII palsies continued to persist, however, all her extraocular movements were intact. The decision to stop methotrexate and continue only with adalimumab was taken.

At the next 6-month follow-up, the patient's family reported that the patient missed five of her doses of adalimumab following her previous appointment because they that she was getting better and did not need them. Her headaches had returned soon after stopping therapy and were consistent with associated eye pain and double vision. The family had restarted adalimumab injections 4 weeks prior to the 6-month follow-up visit, and the patient's symptoms had improved dramatically since resuming the medication. The patient reported some nausea and vomiting, poor appetite, no fevers, and some abdominal pain daily since resuming adalimumab. At the conclusion of this visit, the patient was given instructions to take 40 mg of prednisone for one week and then transition to 20 mg for one week in the morning. Adalimumab 40 mg every other week was continued and the importance of medication compliance was emphasized.

Main Points

- Tolosa-Hunt syndrome is a rare disorder characterized by painful unilateral ophthalmoplegia and headache.
- The pathology of Tolosa-Hunt syndrome can reveal granulomatous inflammation of the wall and septa of the cavernous sinus or superior orbital fissure.
- Corticosteroids are the first-line therapy for Tolosa-Hunt syndrome, but some cases are refractory.
- Tumor necrosis factor inhibition appears to be the effective mode of treatment for corticosteroid-dependent or refractory Tolosa-Hunt syndrome.

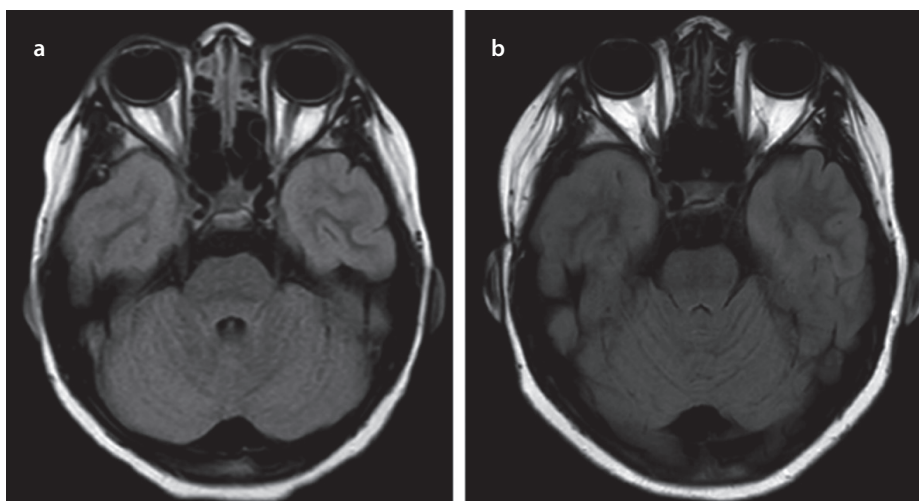


Figure 1. a, b. MRI of head. Axial T2 FLAIR SENSE scan from initial presentation demonstrating dural thickening of the right cavernous sinus (a); Axial FLAIR from two years after initial presentation and following treatment with adalimumab. The scan is unremarkable and demonstrates the remission of active disease (b).

Two months later, the patient, now 12 years old, stated that she had not missed a dose of adalimumab since her last appointment. She reported no headache symptoms during the 8 weeks leading up to the appointment. She denied any eye pain, use of acetaminophen, or use of non-steroidal anti-inflammatory drugs. Five months later, the patient was again headache-free, without eye symptoms, and no further complaints. She reported excellent compliance with adalimumab treatment without any noted side effects of therapy.

Discussion

THS is a rare disease caused by granulomatous inflammation of the cavernous sinus or superior orbital fissure (1). It is ultimately diagnosed by exclusion as is demonstrated by the extensive workup in our patient. Similar symptoms can be present in patients with neoplasms, vascular pathologies, parasellar syndrome, giant cell arteritis, migraines, and numerous other causes of painful ophthalmoplegia (4).

The diagnosis is often made using the IHS definition (5), however, this definition only accounts for paresis of the 3rd, 4th, and 6th cranial nerves despite there being several cases of THS with involvement of the 5th, 7th, and 8th nerves (6-9). To our knowledge there have only been two other reported cases of CN VII palsy in THS (3, 10). Our patient's CN VI palsy complied with the IHS definition and the CN VII palsy was reflective of past cases reported.

CSF abnormalities have not been demonstrated to be helpful in the diagnosis of THS, and a head MRI is typically utilized as the initial diagnostic test to help confirm the diagnosis (3). MRI studies in the literature have typically shown soft tissue changes in the cavernous sinus that can be enhanced with contrast (4, 11, 12). It should be noted, however, that MRI has limited specificity and biopsy of the cavernous sinus dural wall is sometimes needed for cases that present with rapidly progressive neurologic deficits and/or are refractory to steroid therapy (4).

Although the evidence for treatment in pediatrics is limited largely to case reports and case series, the presentation and management is similar to that of adults (3, 13). Corticosteroids have been the mainstay of treatment in THS, and their benefit mostly seems to be limited to reducing periorbital pain (3). It is unclear how beneficial corticosteroids are in maintaining remission of the disease or correcting the palsies associated with THS (4). There have been some reports of the use of azathioprine, methotrexate, mycophenolate mofetil, cyclosporine, infliximab, and

radiotherapy being used as second-line agents for those with biopsy-proven diagnosis, steroid dependence, or recurrent flare-ups that are not well controlled with steroids (2).

Adalimumab is a humanized anti-tumor necrosis factor (TNF) monoclonal antibody which has demonstrated success in treating many rheumatologic conditions (both on and off label), including rheumatoid arthritis, psoriasis, psoriatic arthritis, Crohn's disease, sarcoidosis, uveitis, and juvenile idiopathic arthritis (14, 15). While there has been some demonstrated success with intravenous infliximab (a chimeric monoclonal antibody against TNF) (16, 17) in treating 2 adult patients with THS, there have been no published cases of THS that have been successfully treated with subcutaneous adalimumab to date (13).

Our patient was somewhat unique in the sense that her disease was refractory to corticosteroid therapy. Her symptoms improved moderately with steroid therapy, but she only saw improvement for very short periods of time. The efficaciousness of adalimumab was further emphasized in this case when the patient's family discontinued the patient's methotrexate and adalimumab medication at different stages in her treatment. First, methotrexate was removed while adalimumab remained in place. The patient was stable and continued to improve with adalimumab alone. As the patient became asymptomatic, the adalimumab was stopped by the family, and the patient's severe symptoms returned. Upon resuming her adalimumab, the patient's symptoms resolved, and it appeared that remission had been achieved without the need for any additional therapy.

Conclusion

THS is a rare condition that is characterized by granulomatous inflammation of the cavernous sinus. This case highlights the potential utility of treating pediatric patients with THS using adalimumab, especially in cases that are refractory to corticosteroid therapy or those that may require an alternative to extended courses of corticosteroids.

Informed Consent: Written informed consent was obtained from the parents of the patient's who participated in this study.

Peer-review: Externally peer-reviewed.

Author Contributions: Concept - C.R., J.W.; Design - C.R., J.W.; Supervision - C.R., J.W.; Data Collection and/or Processing - C.R., J.W.; Analysis and/or Interpretation - C.R., J.W.; Literature Search - C.R., J.W.; Writing Manuscript - C.R., J.W.; Critical Review - C.R., J.W.

Conflict of Interest: The authors have no conflict of interest to declare.

Financial Disclosure: The authors declared that this study has received no financial support.

References

- Hunt WE. Tolosa-Hunt syndrome: one cause of painful ophthalmoplegia. *J Neurosurg* 1976; 44: 544-9. [\[CrossRef\]](#)
- Amrutkar C, Burton EV. Tolosa-Hunt Syndrome. In: StatPearls. Treasure Island (FL); 2019.
- Tsirigotaki M, Ntoulis G, Lioumpas M, Voutoufianakis S, Vorgia P. Tolosa-Hunt Syndrome: Clinical Manifestations in Children. *Pediatr Neurol* 2019; 99: 60-3. [\[CrossRef\]](#)
- Kline LB, Hoyt WF. The Tolosa-Hunt syndrome. *J Neurol Neurosurg Psychiatry* 2001; 71: 577-82. [\[CrossRef\]](#)
- Headache Classification Committee of the International Headache Society (IHS) The International Classification of Headache Disorders, 3rd edition. *Cephalalgia* 2018; 38: 1-211. [\[CrossRef\]](#)
- Smith JL, Taxdal DS. Painful ophthalmoplegia. The Tolosa-Hunt syndrome. *Am J Ophthalmol* 1966; 61: 1466-72. [\[CrossRef\]](#)
- Sondheimer FK, Knapp J. Angiographic findings in the Tolosa-Hunt syndrome: painful ophthalmoplegia. *Radiology* 1973; 106: 105-12. [\[CrossRef\]](#)
- Adams A, Warner A. Painful ophthalmoplegia: report of a case with cerebral involvement and psychiatric complications. *Bull Los Angeles Neurol Soc* 1975; 40: 49-55.
- Inzitari D, Sita D, Marconi G, Barontini F. The Tolosa-Hunt syndrome: further clinical and pathogenetic considerations based on the study of eight cases. *J Neurol* 1981; 224: 221-8. [\[CrossRef\]](#)
- Cerisola A, Gonzalez G, Scavone C. Tolosa-Hunt syndrome preceded by facial palsy in a child. *Pediatr Neurol* 2011; 44: 61-4. [\[CrossRef\]](#)
- Yousem DM, Atlas S, Grossman R, Sergott R, Savino P, Bosley T. MR imaging of Tolosa-Hunt syndrome. *Am J Neuroradiol* 1989; 10: 1181-4.
- Goto Y, Hosokawa S, Goto I, Hirakata R, Hasuo K. Abnormality in the cavernous sinus in three patients with Tolosa-Hunt syndrome: MRI and CT findings. *J Neurol Neurosurg Psychiatry* 1990; 53: 231-4. [\[CrossRef\]](#)
- Perez CA, Evangelista M. Evaluation and Management of Tolosa-Hunt Syndrome in Children: A Clinical Update. *Pediatr Neurol* 2016; 62: 18-26. [\[CrossRef\]](#)
- Gerriets V, Khaddour K. Tumor Necrosis Factor (TNF) Inhibitors. In: StatPearls. Treasure Island (FL); 2019.
- Lapadula G, Marchesoni A, Armuzzi A, Blandizzi C, Caporali R, Chimenti S, et al. Adalimumab in the treatment of immune-mediated diseases. *Int J Immunopathol Pharmacol* 2014; 27: 33-48. [\[CrossRef\]](#)
- Halabi T, Sawaya R. Successful Treatment of Tolosa-Hunt Syndrome after a Single Infusion of Infliximab. *J Clin Neurol* 2018; 14: 126-7. [\[CrossRef\]](#)
- O'Conner G, Hutchinson M. Tolosa-Hunt syndrome responsive to infliximab therapy. *J Neurol* 2009; 256: 660-1. [\[CrossRef\]](#)