

# Plantar Fibromatosis/Fasciitis in Ankylosing Spondylitis: Why/Where to Inject?

Berkay Yalçinkaya<sup>1</sup>, Ahmet Furkan Çolak<sup>1</sup>, Murat Kara<sup>1</sup>, Levent Özçakar<sup>1</sup>

To the Editor,

A 47-year-old female patient was presented with bilateral ankle/foot pain and difficulty in weight bearing on both feet. She noted that her complaints had begun 4 months ago and worsened over time (and during standing). The patient also had widespread pain in the neck/back and around the shoulder/hip. She did not describe any swelling, redness, warmth, weakness, paresthesia, or other additional symptoms. Her medical history was unremarkable except for ankylosing spondylitis (AS). She had used different anti-TNF- $\alpha$  (Tumour Necrosis Factor alpha) drugs (adalimumab, golimumab, and etanercept) since the diagnosis (for almost 3 years). Due to side effects or ineffectiveness, secukinumab and then upadacitinib were also given for about 2 months, with no better effects.

In the physical examination, pain and tenderness were detected over the plantar fasciae. Ultrasound (US) examination revealed bilateral edematous plantar fasciae. Further, elongated fusiform nodular appearances were also detected on both sides (these nodular lesions were tender to sono-palpation) with hypoecho-genicity of the fascia on the left side (Figure 1). These findings were consistent with bilateral plantar fibromatosis and left-sided plantar fasciitis. Ultrasound-guided injection (a combination of 2 mL prilocaine and 1 mL betamethasone) was administered bilaterally for the areas of fibromatosis (inside the nodular lesion) and the deep layers of the plantar fascia (Video 1). The patient considerably benefited from these injections (visual analog scale score decreased from 10 to 5 in 10 days). At the third week follow-up visit, plantar fascia thickness significantly decreased (from 6.0 mm to 3.4 mm on the left side and from 4.6 mm to 3.4 mm on the right side). Fibromatosis lesions did not change significantly. In addition to upadacitinib, she was also prescribed acetaminophen (100 mg/day) and sulfasalazine (2 g/day) for AS. Her widespread pain also decreased mildly with this new treatment (visual analog scale score decreased from 10 to 6 in 3 weeks). The patient is still under regular follow-up. Informed consent was obtained from the patient.

#### ORCID iDs of the authors:

B.Y. 0000-0001-6069-4575;  
A.F.Ç. 0000-0003-4034-1558;  
M.K. 0000-0003-0125-4865;  
L.Ö. 0000-0002-2713-4071.

**Cite this article as:** Yalçinkaya B, Çolak AF, Kara M, Özçakar L. Plantar fibromatosis/fasciitis in ankylosing spondylitis: why/where to inject?. *Eur J Rheumatol.* 2025, 12(2), 0112, doi: 10.5152/eurjrheum.2025.24112.

Department of Physical Medicine and Rehabilitation, Hacettepe University School of Medicine, Ankara, Türkiye

Corresponding author:  
Berkay Yalçinkaya  
E-mail: berkay0lka@gmail.com

Received: November 2, 2024  
Revision Requested: November 14, 2024  
Last Revision Received: November 15, 2024  
Accepted: January 10, 2025  
Publication Date: May 16, 2025

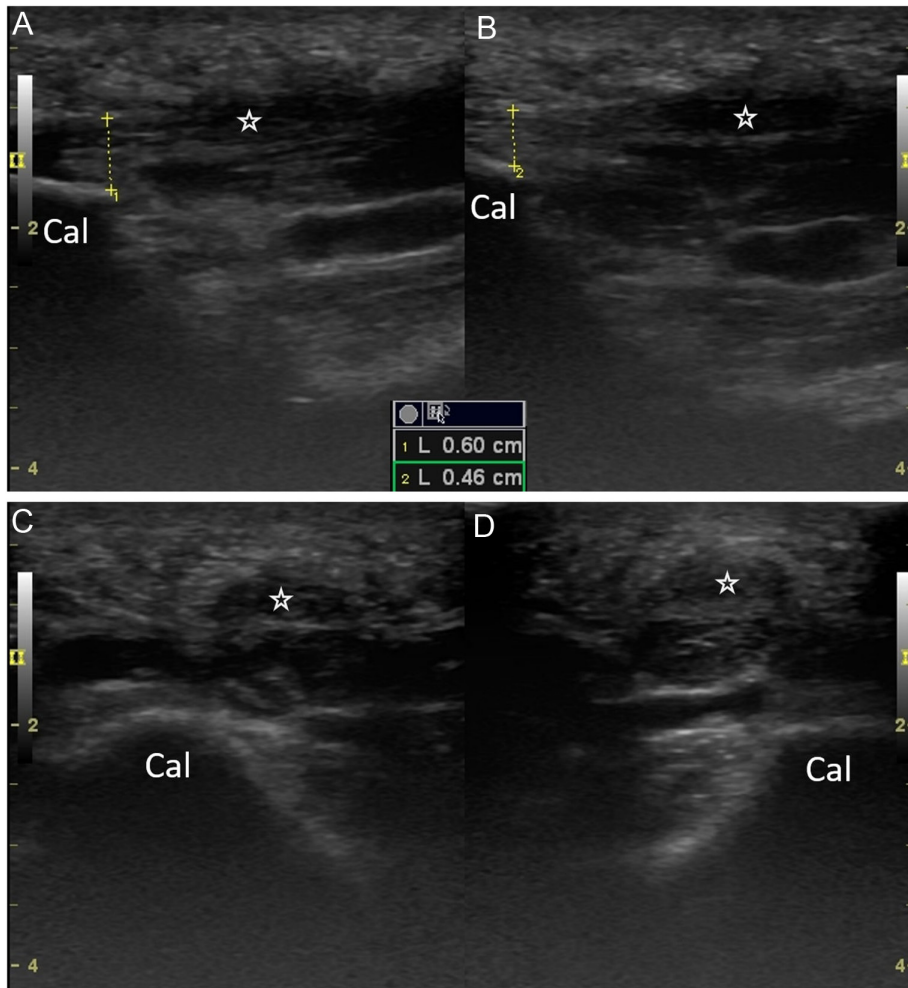
Copyright©Author(s) - Available online at  
www.eurjrheumatol.org.

Content of this journal is licensed under a Creative Commons Attribution-NonCommercial 4.0 International License.



Plantar fibromatosis (PF), also known as Ledderhose disease, can be identified as a benign, relatively rare, fibroblastic/proliferative disorder of the superficial plantar aponeurosis. It is characterized by nodular formations within the plantar fascia and typically presents with pain, swelling, and palpable mass on the plantar surface.<sup>1</sup> Its exact pathophysiology is still unclear, but some etiologic factors comprise repetitive trauma, overuse, alcohol consumption, certain medications (anti-epileptics, anti-TNF- $\alpha$ ), genetic factors, diabetes mellitus, and other proliferative diseases. For its diagnosis, US may be useful in determining the size/number of the nodule(s), and its vascularity (Doppler activity). These nodules are generally seen as iso-/hypo-echoic and heterogeneous with(out) hyperechoic septae.<sup>1</sup> In the differential diagnoses, the most likely conditions would be plantar fasciitis and chronic rupture of the plantar fascia; but, in most instances, clinical features and imaging findings are enough for the (differential) diagnosis. Further, as observed in our patient, it is not uncommon to find plantar fasciitis accompanying PF.<sup>2</sup>

Treatment options for PF encompass activity modification, anti-inflammatory drugs, physical therapy, exercises, orthotics/pads, collagenase or steroid injection, tamoxifen, extracorporeal shock wave therapy, and radiotherapy.<sup>1</sup> Two patients with PF following anti-TNF- $\alpha$  treatment have previously been reported. In both patients, the plantar nodules decreased in size and became stable after the discontinuation of the drugs (adalimumab and etanercept).<sup>3</sup> In Dupuytren's contracture, a disease similar to PF, TNF- $\alpha$  also plays an important role in the conversion of fibroblasts into myofibroblasts via the Wnt signaling pathway.<sup>4</sup> A similar pathogenesis might be effective in the development of PF in patients under anti-TNF- $\alpha$  therapy. However, the current literature on the association between anti-TNF- $\alpha$  treatment and the occurrence of PF is extremely limited.



**Figure 1.** Comparative longitudinal (A and B) and axial (C and D) ultrasound images of the plantar fasciae demonstrate elongated fusiform hypoechoic nodules (stars). Note the swollen/thickened left (A) and right (B) plantar fasciae measurements (yellow lines). Cal, calcaneus.

Due to the possible mechanism(s) mentioned above, retroperitoneal fibrosis and mesenteric fibromatosis have also been reported in the current literature.<sup>5,6</sup> Herein, we speculate that both the anti-TNF- $\alpha$  treatment and the inflammatory disease (AS) might have caused PF. We underscore the importance of recognizing other possible underlying pathologies or drug side effects when the expected treatment outcome is not achieved in rheumatic diseases. In this sense, our patient had severe plantar pain caused by PF, which was treated by local injection and systemic treatment.

Herein, we also aimed to demonstrate the injection technique for relevant cases, i.e., for targeting the nodule as well as the deep layers

of the plantar fascia. Although no exact injection technique has been described in the literature, we believe that injecting the steroid directly into the nodule (deactivating the myoblasts) and adjacent to the deep layers of the fascia (suppressing the inflammation) would be more effective for treating both PF and plantar fasciitis.<sup>7</sup> Last but not least, US maintains its unique role in both diagnosis and treatment, particularly where traditional approaches lack favorable outcomes in rheumatologic diseases.

**Data Availability Statement:** N/A.

**Informed Consent:** Informed consent was obtained from the patient who agreed to take part in the study.

**Peer-review:** Externally peer-reviewed.

**Author Contributions:** Concept – B.Y., A.F.Ç.; Design – B.Y.; Supervision – M.K., L.Ö.; Resources – B.Y., A.F.Ç.; Materials – B.Y., M.K.; Data Collection and/or Processing – B.Y., M.K., A.F.Ç.; Analysis and/or Interpretation – B.Y., A.F.Ç.; Literature Search – B.Y.; Writing – B.Y., A.F.Ç., M.K., L.Ö.; Critical Review – M.K., L.Ö.

**Declaration of Interests:** The authors have no conflict of interest to declare.

**Funding:** The authors declared that this study has received no financial support.

**Video 1:** Real-time ultrasound guidance during the intranodular injection and the injection into the deep layer of the plantar fascia. Plantar fibromatosis (dashed lines), injection material (arrow). The needle (arrowhead) is inserted using the direct in-plane technique (Note that the video is accelerated to double speed). Cal, calcaneus; FDB, flexor digitorum brevis; HFP, heel fat pad; PF, plantar fascia.

## References

1. Meyers AL, Marquart MJ. Plantar fibromatosis. In: *StatPearls*. Treasure Island (FL): StatPearls Publishing; February 28, 2024.
2. Griffith JF, Wong TY, Wong SM, Wong MW, Metreweli C. Sonography of plantar fibromatosis. *AJR Am J Roentgenol*. 2002;179(5):1167-1172. [\[CrossRef\]](#)
3. Couderc M, Kemeny JL, Lhoste A, Soubrier M, Dubost JJ. Active plantar fibromatosis occurring under Anti-TNF $\alpha$  therapy for spondyloarthritis. *Joint Bone Spine*. 2017;84(3):371-372. [\[CrossRef\]](#)
4. Verjee LS, Verhoekx JS, Chan JK, et al. Unraveling the signaling pathways promoting fibrosis in Dupuytren's disease reveals TNF as a therapeutic target. *Proc Natl Acad Sci U S A*. 2013;110(10):E928-E937. [\[CrossRef\]](#)
5. Manganelli S, Giannitti C, Galeazzi M, Rossi M. Retroperitoneal fibrosis following a long-standing etanercept treatment in a spondyloarthritis patient. *Joint Bone Spine*. 2018;85(3):389-390. [\[CrossRef\]](#)
6. Abdelqader A, Goud A, Fleisher AS. Mesenteric fibromatosis in Crohn's disease as a potential effect of adalimumab. *ACG Case Rep J*. 2016;3(3):184-186. [\[CrossRef\]](#)
7. Gurcay E, Kara M, Karahmet OZ, Ata AM, Onat ŞŞ, Özçakar L. Shall we inject superficial or deep to the plantar fascia? An ultrasound study of the treatment of chronic plantar fasciitis. *J Foot Ankle Surg*. 2017;56(4):783-787. [\[CrossRef\]](#)