

This article has been retracted. You may access the details of retraction via DOI: 10.5152/eurjrheum.2021.2021.

A clinical case of laptop-generated Erythema ab igne

Yelyzaveta Yehudina¹ , Svitlana Trypilka² 

Heat erythema [hot water bottle rash, infrared radiation, Erythema ab igne (EAI)] is a reticulated erythema or pigmented dermatosis resulting from the multiple effects of moderate heat or infrared radiation. EAI, also known as “toasted skin syndrome” or “fire stains”, is a localized skin lesion, manifesting itself as reticular hyperpigmentation, dark erythema, epidermal atrophy, and telangiectasias (1).

EAI is caused by chronic, multiple, moderate heat exposures originating from an external heat source. This pathology has now become a topical issue among laptop users who place the computers on their lap while working (2). Although the pathogenic mechanisms in EAI are under-explored, some studies demonstrate that moderate heat has a synergistic effect with an ultraviolet irradiation and causes DNA denaturation in squamous cell carcinomas in vitro (3). Although EAI is generally identified by clinical diagnosis, histological data may significantly assist in differential diagnosis.

Rheumatologists consider this pathology to be of a clinical interest, as skin conditions may resemble skin lesions attributed to systemic connective tissue disorders. We present the case of a young female patient with EAI subjected to various examinations intended to ascertain the genesis of the changes in the skin.

The patient, 34 years old, complained of consistent changes in the skin on the left thigh and left knee joint. There were no further complaints. Her medical history revealed gradual increase in the change over the past year. She consulted a dermatologist and a vascular surgeon to rule out the common pathologies. No pathological changes were identified. However, she was prescribed a course of Pentoxifylline and local corticosteroid for a month with no apparent improvement. She was then referred to a rheumatologist to confirm or eliminate the diagnoses of vasculitis, scleroderma, or systemic lupus erythematosus onset.

She was in moderately good condition. The left thigh had sites of reddish-purple hyperpigmentation with indeterminate contours, there was no pain at palpation, and skin and subcutaneous tissue density were not compromised. The thigh skin was easily folded. The hyperpigmented sites paled and pigmentation was insignificant when pressed, after

ORCID iDs of the authors:
Y.Y. 0000-0001-8702-5638;
S.T. 0000-0001-6630-9893

Cite this article as: Yehudina Y, Trypilka S. A clinical case of laptop-generated Erythema ab igne. Eur J Rheumatol 2021; 8(2): 117-8.

¹ Department of Rheumatology, Institute of Rheumatology, Kyiv, Ukraine

² Department of Rheumatology, Communal Non-Commercial Enterprise of Kharkov Regional Council “Regional Clinical Hospital”, Kharkiv, Ukraine

Address for Correspondence:

Yelyzaveta Yehudina; Department of Rheumatology, Institute of Rheumatology, Kyiv, Ukraine

E-mail: elizavetaegudina@gmail.com

Submitted: August 22, 2020

Accepted: October 23, 2020

Available Online Date: February 9, 2021

Copyright © Author(s) - Available online at www.eurjrheumatol.org.

Content of this journal is licensed under a Creative Commons Attribution-NonCommercial 4.0 International License.

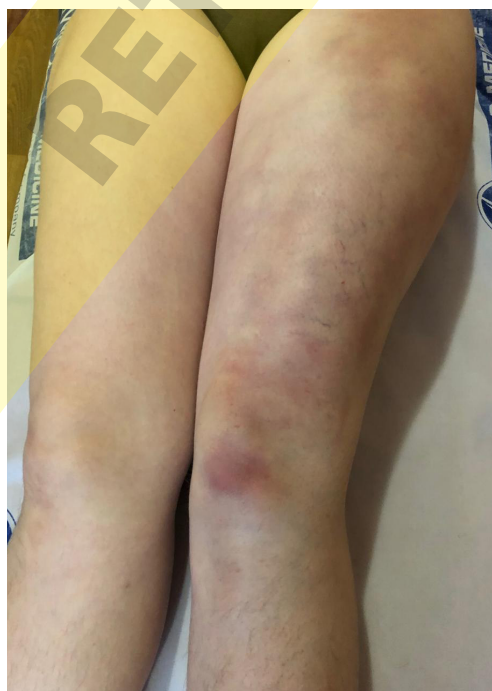

Figure 1. The appearance of the patient's skin integument at the time of consultation with the rheumatologist.

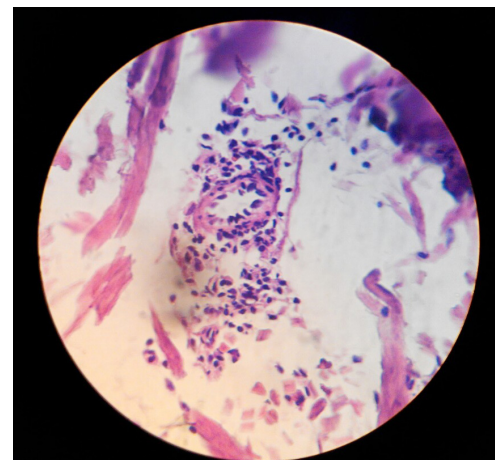


Figure 2. Histopathological alterations of the patient's skin. Minimal alterations of the collagen fibers. Staining by hematoxylin and eosin. X300.

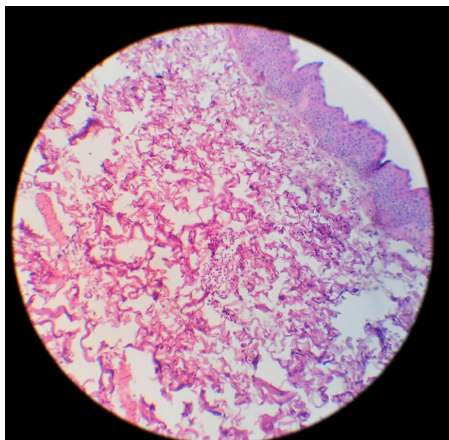


Figure 3. Histopathological alterations of the patient's skin. Perivascular neutrophil infiltration of the derma. Staining by hematoxylin and eosin. X300.

which they returned to their initial color (Figure 1). Examination of the internal organs and blood and urine analysis were unremarkable.

Screening for autoimmune conditions did not reveal any disorders. Tests for cryoglobulins and hepatitis B and C produced negative results. The X-ray of chest did not reveal any pathology.

The patient was subjected to the skin biopsy of the anterior left thigh (Figure 2, Figure 3). The study of the extracted biopsy material, with hematoxylin and eosin staining, showed thinned-out sites (atrophies) of the epidermis, hyperkeratosis with scaling of the cornified cells, parakeratosis occurring in the epidermis, vacuole dystrophy of single keratinocytes, smoothing-down of the dermal papillae, densification of the collagen fibers, interstitial swelling, and perivascular inflammatory infiltrates containing accumulations of microxyphil leukocytes and mononuclear cells.

Having obtained a careful anamnesis of the patient, we discovered that for half a year she had been working from home, holding the laptop on her lap. The heat-producing battery of the laptop was located on the left side. So, we concluded that it was a case of heat erythema or EAI.

Heat erythema is an extremely rare condition, drawing attention of both rheumatologists and adjunct specialists. The most important treatment for this pathology is the immediate eradication of heat source. For most cases, treatment with drugs is not required.

Informed Consent: Written informed consent was obtained from the patient.

Peer-review: Externally peer-reviewed.

Author Contributions: Concept - S.T.; Supervision - Y.Y.; Materials - S.T.; Data Collection and/or Processing - S.T.; Literature Search - Y.Y.; Writing Manuscript - Y.Y.; Critical Review - Y.Y.

Conflict of Interest: The authors have no conflict of interest to declare.

Financial Disclosure: The authors declared that this study has received no financial support

References

1. Kligman LH. Intensification of ultraviolet-induced dermal damage by infrared radiation. *Arch Dermatol Res* 1982; 272: 229-38. [\[Crossref\]](#)
2. Guarneri C, Tchernev G, Wollina U, Lotti T, Vaccaro M. Erythema ab igne caused by laptop computer. *Open Access Maced J Med Sci* 2017; 25: 490-2. [\[Crossref\]](#)
3. Roth D, London M. Acridine probe study uno synergistic DNA-denaturing action of heat and ultraviolet light in squamous cells. *J Inves Dermatol* 1977; 69: 368-72. [\[Crossref\]](#)