

# Efficacy of a sequential treatment by belimumab in monogenic systemic lupus erythematosus

Lujayn Akbar , Razan Alsagheir , Sulaiman M. Al-Mayouf 

## Abstract

The objective of the study was to report the safety and potential therapeutic effect of belimumab in monogenic systemic lupus erythematosus (SLE). Consecutive children with monogenic SLE treated with belimumab were evaluated retrospectively. Response parameters assessment was completed at the time of initiation of belimumab, at 6 months, and last follow-up visit. Response parameters comprised physician global assessment (physician GA) and parent global assessment (parent GA), global disease activity as measured by SLE disease activity index (SLEDAI), and daily glucocorticoids dose. Undesirable events affecting patients during treatment were also collected. Six children with monogenic SLE proved by genetic testing (five patients with C1q deficiency and one patient with deoxyribonuclease II (DNase II) deficiency), failed glucocorticoids and sequential immunosuppressive medications. Belimumab was added to glucocorticoids and current immunosuppressive medications. The main indications for belimumab initiation were mucocutaneous disease, arthritis, and inability to taper glucocorticoids. All patients tolerated belimumab infusion. No serious events were reported. However, one patient was lost to follow-up and died because of sepsis. Compared to the baseline values, there was an improvement in physician GA, parent GA, and SLEDAI, and a notable reduction in the need of daily corticosteroids. However, there were no significant changes in the complement and ds-DNA antibody levels. Belimumab can be considered as an adjunctive therapeutic option for patients with refractory monogenic SLE. Further follow-up and more patients needed to confirm this finding and a larger prospective study is required for more definitive conclusions.

**Keywords:** Belimumab, biologic agents, monogenic lupus, systemic lupus erythematosus

### ORCID iDs of the authors:

L.A. 0000-0002-9758-0376;  
R.A. 0000-0003-0160-9080;  
S.M.A. 0000-0003-0142-6698.

**Cite this article as:** Akbar L, Alsagheir R, Al-Mayouf SM. Efficacy of a sequential treatment by belimumab in monogenic systemic lupus erythematosus. *Eur J Rheumatol* 2020; 7(4): 184-9.

Department of Pediatric Rheumatology, King Faisal Specialist Hospital and Research Center, Riyadh, Saudi Arabia

### Address for Correspondence:

Sulaiman M. Al-Mayouf; Department of Pediatric Rheumatology, King Faisal Specialist Hospital and Research Center, Riyadh, Saudi Arabia

E-mail: mayouf@kfshrc.edu.sa

Submitted: May 16, 2020

Accepted: July 17, 2020

Available Online Date: September 08, 2020

Copyright@Author(s) - Available online at [www.eurjrheumatol.org](http://www.eurjrheumatol.org).

Content of this journal is licensed under a Creative Commons Attribution-NonCommercial 4.0 International License.



## Introduction

Systemic lupus erythematosus (SLE) is a systemic autoimmune disease with clinical heterogeneity and complex etiopathogenesis. The precise etiology of SLE remains incompletely defined. However, identifications of single-gene defects, including complement component *C1q* mutation have contributed in better understanding of the clinical variability, and recognition of rare variants of childhood SLE (cSLE), known as monogenic SLE (1-4). Typically, patients with monogenic SLE have early onset severe disease, especially with mucocutaneous manifestations, and a strong family history of SLE (5-7). These findings suggested that monogenic SLE represents a distinctive entity and might differ from the sporadic SLE. The clinical presentation of monogenic SLE has a wide variety of manifestations and unpredictable course and may overlap with other disorders such as monogenic interferonopathies (8, 9). Despite advances in understanding the immune mechanisms involved in SLE pathogenesis, there is no effective therapy that can halt the disease progression yet. Also, it is not unusual that while treating a patient, the physician considered off-label medication as therapeutic options for refractory cases (10). Belimumab gained much attention in the treatment of adult patients with SLE, particularly with arthritis and skin involvement. Recently, belimumab has been approved for patients with cSLE aged 5 years and older. The available data in cSLE are still limited, and its use in monogenic SLE is lacking (11-13).

Here, to the best of our knowledge, we report for the first time the therapeutic effect of belimumab in a cohort of monogenic SLE.

## Methods

It was a descriptive, retrospective cohort study of all children with monogenic SLE seen and treated with belimumab at a single tertiary referral hospital between 2016 to 2020. All patients had genetically proven single-gene defect and met the Systemic Lupus International Collaborating Clinics criteria (14). Data were collected from the hospital electronic medical records for demographic data, the age

at onset, clinical and laboratory findings, and history of previous and current medication for SLE. Also, data were collected for the response to therapeutic intervention by measuring disease activity at the time of initiation of belimumab, then at 6 months, and at the last follow-up visit, using Systemic Lupus Erythematosus Disease Activity Index (SLEDAI) (15). Also, we considered the physician global assessment (Physician GA), parent global assessment (Parent GA) as measured on a visual analog scale with a range from 0 to 10 (0=very poor; 10=very well), and daily corticosteroid dose requirement.

### Ethical considerations

The data were part of a study conducted in accordance with the Declaration of Helsinki and approved by the Ethics committee of the Research Affairs Council (RAC) at our institution (RAC approval no. 2191122). All the data were collected from the routine medical assessment. All data were collected anonymously, and the confidentiality of the patients was protected. All data were exclusively used for the present study. Informed consent for genetic testing as part of patient care was obtained from the parents at the time of blood extraction.

### Results

Six consecutive patients with monogenic SLE treated with belimumab were enrolled. Five patients had *C1q* deficiency, and one patient had deoxyribonuclease II (DNase II) deficiency. Belimumab was added after the failure of intensive treatment using the standard therapy, at the dose of 10 mg/kg every 2 weeks for 3 doses, then every 4 weeks. The main indications for belimumab initiation were refractory mucocutaneous, arthritis, renal manifestations, and inability to taper glucocorticoids. All patients tolerated belimumab infusion. Table 1 summarizes the clinical manifestations and previous treatment.

### Main Points

- Monogenic systemic lupus erythematosus (SLE) represents a distinctive entity and might be different from the sporadic SLE.
- Limited data exist regarding the treatment of monogenic SLE.
- Our study demonstrates that belimumab can be considered as an adjunctive therapeutic option for patients with refractory monogenic SLE.

## Case Presentation

### Case 1

A 10-year-old girl presented at the age of 2 years to the local hospital with extensive mucocutaneous lesions, scarring diffuse alopecia, and arthritis with a spastic gait. Also, she had recurrent infections. At the age of 4 years, she was referred to our pediatric rheumatology service for further assessment. Complete blood count revealed pancytopenia with white blood cell count of  $2.4 \times 10^9$  cells/L, platelet count of  $94 \times 10^9$  cells/L with an elevated erythrocyte sedimentation rate of 78 mm/h. Also, she had antinuclear antibody (ANA) 1:1280 (<1:140), and anti-double stranded DNA (ds-DNA) 646 IU/mL (0-200). At this point in time and based on the early onset presentation and the constellation of clinical and laboratory findings, monogenic SLE was considered. Whole-exome sequencing (WES) identified homozygous *C1q* variant. She was treated with prednisone (1 mg/kg/day), hydroxychloroquine (5 mg/kg/day), mycophenolate mofetil (MMF) (40 mg/kg/day), and monthly intravenous immunoglobulin (IVIG) infusion with poor response. Therefore, she was offered different immunosuppressive medications, including two doses of rituximab but with a partial improvement. Then, belimumab was added to her treatment, and she showed a remarkable improvement in mucocutaneous manifestations and arthritis. However, she lost her follow-up visits at our hospital. We have been notified by her pediatrician at the local hospital that she passed away after developing a chest infection complicated by a septic shock. Unfortunately, details about the intensive care unit course, and isolated organisms were not available.

### Case 2

An 8-year-old boy born to consanguineous parents and presented at the age of 2 months with mucocutaneous manifestations. Family had two affected sisters, both died at a young age with complications of refractory SLE. Laboratory results revealed high inflammatory markers and high ANA, ds-DNA antibodies, and low C3 level. WES identified homozygous *C1q* mutation. Despite aggressive management, he continued to have an active disease for 7 years. After the initiation of belimumab, he showed improvement in disease activity measures and daily corticosteroid requirement.

### Case 3

A 21-year-old boy presented at the age of 4 years with hematological and mucocutaneous manifestations associated with high ANA and ds-DNA with undetected *C1q* level. He was diagnosed as monogenic SLE based on the mo-

lecular genetic findings. He was treated with glucocorticoids, immunosuppressive medications and IVIG. He had a refractory disease course and developed biopsy proven membranoproliferative glomerulonephritis. After belimumab was initiated, proteinuria improved, allowing for the discontinuation of glucocorticoids and MMF. While he was on belimumab, he had static nonnephrotic range proteinuria with normal creatinine levels. However, few months after MMF cessation, serum creatinine levels and proteinuria increased. Hence, MMF was reintroduced and serum creatinine levels and proteinuria were significantly improved.

### Case 4

An 8-year-old boy presented to the local hospital at the age of 3 years with polyarthritis and high ANA and ds-DNA. He was managed as polyarticular juvenile arthritis with methotrexate and adalimumab. Interestingly, he had a long-standing headache associated with bilateral papilledema required acetazolamide treatment. Brain magnetic resonance imaging (MRI) showed white matter changes. Plain radiography of both hands revealed nonerosive arthritis. Based on the constellation of clinical and laboratory finding, the diagnosis of SLE was made. Furthermore, molecular genetic findings identified homozygous *DNase II* variant. Belimumab was initiated, and at a 3-month follow-up visit, joint pain significantly improved. However, he continued to have deformed joints. Also, headache and papilledema resolved completely, and acetazolamide was discontinued.

### Cases 5 and 6

Two siblings born to consanguineous parents. The eldest one is a 9-year-old girl presented at the age of 2 years with disfiguring facial lesions and diffuse scarring alopecia. The other sibling, a 5-year-old boy, had a discoid facial rash. Lately, he developed spastic gait and brain MRI showed basal ganglia calcification. Both were failure to thrive and recurrent infections, mainly localized skin infections and otitis media. Both had high ANA and ds-DNA. However, serum complement levels (C3 and C4) were within the normal limit. WES identified homozygous *C1q* variant. They had a refractory disease course despite of intensive, sequential immunosuppressive treatment. Since belimumab initiation, there was no improvement in the cutaneous manifestations.

### Clinical assessment

None of the patients achieved remission but there was improvement in response parameters including SLEDAI, Physician GA, and Parent GA, associated with reduction in daily gluco-

**Table 1.** Summary of demographics, disease characteristics, and previous therapy at baseline.

	Case 1	Case 2	Case 3	Case 4	Case 5	Case 6
Age (years)	10	8	21	8	9	5
Gender	Female	Male	Male	Male	Female	Male
Age at onset (months)	24	2	48	36	24	24
Diagnosis	C1q deficiency	C1q deficiency	C1q deficiency	DNase II deficiency	C1q deficiency	C1q deficiency
Disease duration (years)	8	8	17	5	8	3
Disease manifestations	Mucocutaneous	Mucocutaneous	Mucocutaneous	Mucocutaneous	Mucocutaneous	Mucocutaneous
	Arthritis	Arthritis	Lupus nephritis class III/IV	Arthritis with fixed deformities	Hematologic	Hematologic
	Lupus nephritis	Lupus nephritis class V	Hematologic	Lupus nephritis class V	Recurrent infections	NPSLE
	Hematologic	Restrictive pulmonary disease	Recurrent infections	Hematologic	Recurrent infections	Recurrent infections
	NPSLE	Recurrent infections		NPSLE		
	Interstitial pneumonitis					
	Dilated ventricle					
	Recurrent infections					
ANA	1:1280	1:2560	1:320	1:1280	1:640	1:2560
Medications	Steroids	Steroids	Steroids	Steroids	Steroids	Steroids
	IVIg	IVIg	IVIg	Adalimumab	IVIg	IVIg
	HcQ	HcQ	HcQ	HcQ	HcQ	HcQ
	MMF	MMF	MMF	MMF	MTX	
	MTX	MTX	AZA	MTX	AZA	
	AZA	AZA		Rituximab	CYC	
	CYC	CYC			Rituximab	
	CSA	CSA				
	Rituximab	Rituximab				
Belimumab duration (months)	11	9	63	10	3	3

SLE: systemic lupus erythematosus; NPSLE: neuropsychiatric SLE; ANA: antinuclear antibodies; IVIG: intravenous immunoglobulin; HcQ: hydroxychloroquine; MMF: mycophenolate mofetil; MTX: methotrexate; AZA: azathioprine; CYC: cyclophosphamide; CSA: cyclosporine.

**Table 2.** Summarized results of response to belimumab during follow-up period.

	Case 1	Case 2	Case 3	Case 4	Case 5	Case 6
<b>SLEDAI</b>						
Baseline	19	7	9	14	4	2
6 months	9	2	4	2	-	-
Last visit	7	2	0	2	1	6
<b>Physician GA</b>						
Baseline	3	4	4	3	3	6
6 months	7	6	7	8	-	-
Last visit	7	7	7	9	7	7
<b>Parent GA</b>						
Baseline	2	5	4	3	4	5
6 months	6	7	4	9	-	-
Last visit	6	7	8	9	7	7
<b>Mean daily steroid dose mg/day*</b>						
Baseline	7.5	7.5	12.5	20	5	5
6 months	10	5	5	5	-	-
Last visit	7	5	0	0	5	10
<b>ds-DNA antibodies IU/mL (&lt;200)</b>						
Baseline	646	453	63	1294	54.7	633.2
6 months	-	478.3	83	-	-	-
Last visit	-	485.1	34.4	947	22.8	175.2
<b>C3 g/L (0.9-1.8)</b>						
Baseline	1.6	0.4	1.2	0.6	1.3	1.3
6 months	1.8	0.4	1.4	0.6	-	-
Last visit	1.9	0.4	1.1	0.7	1.5	1.5
<b>C4 g/L (0.1-0.4)</b>						
Baseline	0.3	0.0	0.4	0.1	0.3	0.2
6 months	0.3	0.0	0.2	0.1	-	-
Last visit	0.4	0.0	0.3	0.1	0.4	0.2
<b>Urine protein/creatinine ratio mg/mmol (&lt;30)</b>						
Baseline	160.6	46.4	225	50	24	23
6 months	160.6	48.1	43.5	14.6	-	-
Last visit	131.4	46.8	41.6	15.6	-	-

\*Prednisone equivalent.

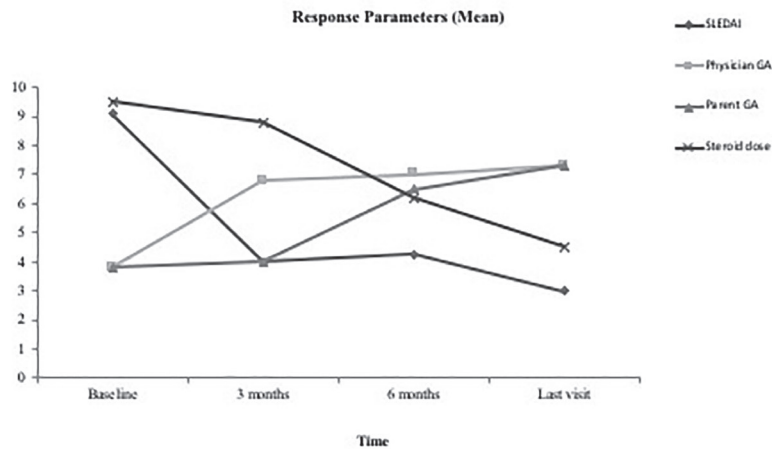
SLEDAI: SLE Disease Activity Index; Physician GA: physician global assessment; Parent GA: parent global assessment; Anti-dsDNA: anti-double-stranded DNA; C3: complement C3; C4: complement C4.

corticoids dose. Complement levels were static and anti-ds-DNA showed a variable response. All patients tolerated belimumab with no significant adverse events. One patient was lost to follow-up, and we have been notified by the

local hospital that she died because of sepsis. Table 2 summarizes the results of response to belimumab during follow-up period. Figure 1 shows the changes in the response parameters during the treatment period.

## Discussion

Monogenic SLE is a rare subtype of cSLE caused by single-gene defects and characterized by early onset disease with a wide spectrum of clinical features and a strong family history of SLE (2, 3, 6). Complement deficiency, namely deficiency, is frequently associated with *C1q* (16). However, depending on the gene defect, an affected individual carries a risk for development of SLE manifestations and immunodeficiency status (17). Based on the similarities in immunopathogenesis with entities characterized by immune dysregulation, monogenic SLE may overlap with primary interferonopathies (9, 18, 19). Therefore, patients with monogenic SLE frequently develop recurrent infections because of the disease itself, underlying immune dysregulation and the concurrent medication, including glucocorticoids and immunosuppressive agents. The treatment of monogenic SLE represents a challenge with limited nonspecific conventional therapeutic agents, including glucocorticoids and immunosuppressive medications (10). There are some reports of a temporary improvement of cutaneous lesions in *C1q*-deficient SLE patients after using fresh frozen plasma (FFP) infusion (20). However, it is difficult to consider a regular FFP infusion as a standard therapeutic option, especially with a short-lived response. The effect of allogenic hematopoietic stem cell transplantation in *C1q*-deficient SLE is promising. However, the procedure carries a remarkable risk (21). Despite advances in understanding the immunopathogenesis of SLE and the notable development of a biologic treatment that has an encouraging impact on the management of several autoimmune diseases, still the implementation of the biologic treatment in cSLE is limited; most of the previous reports focused on the therapeutic role of rituximab in lupus nephritis (22). Belimumab, a monoclonal humanized IgG antibody that inhibits B-lymphocyte stimulator, causes a decrease B cell number and regulates its function. It has shown favorable results in adults with active SLE, particularly those with cutaneous disease and arthritis (23). Recently, belimumab became the first biologically approved treatment for cSLE. The efficacy and safety of belimumab in cSLE is generally consistent with its profile in adult SLE (10, 11). Here, we report for the first time the use of belimumab combined with conventional treatment in patients with refractory monogenic SLE (*C1q* deficiency and DNase II deficiency). Interestingly, four patients treated with monoclonal anti-CD20 antibody had sequential B cell depleting therapy. Variable response measures were obtained. Remarkable improvement in mucocutaneous manifestations was observed in all patients af-



**Figure 1.** Changes in response parameters over a period of 6 months after belimumab treatment.

ter adding belimumab. Also, two patients with arthritis showed a dramatic improvement, and arthritis resolved completely. However, a patient with DNase II deficiency continued to have deforming arthropathy without active synovitis. Of note, a similar finding has been seen in a previous report (9). Two patients discontinued glucocorticoids, while the need for daily glucocorticoids minimized in three patients over at least 6-month follow-up interval. One patient (case 6) had a disease flare and more corticosteroid treatment, which was attributed to medications incompliance. There was a sustained improvement in SLEDAI in five patients, as early as 3 months after belimumab initiation. However, certain parameters did not improve, such as anti-ds-DNA level (case 2). Among four patients with lupus nephritis treated with a combination of belimumab and MMF, two patients showed a notable reduction in the quantitative proteinuria. It is worth stating that this combination might provide a better response for nephritis as reflected by the degree of proteinuria and creatinine levels as shown in case 3. Of note, this combination has been reported in adult studies to induce remission in lupus nephritis. Our observation is in line with the improvement seen among patients sporadic cSLE (12, 13). Belimumab was well tolerated, with no significant adverse events. However, one patient completed 11-month treatment, she developed sepsis and died at the local hospital. All other patients did not experience any documented infection after the addition of belimumab.

Considering the pathogenesis resemblance with monogenic interferonopathies, more novel approaches comprising Janus-kinase (JK) inhibitors such as baricitinib with interferon-blocking activity may represent a therapeutic option in monogenic SLE (8, 24). JK inhibitor

has not been used in our patients because it was not available at our institution.

This study has limitations, it is an anecdotal retrospective report of a small number of patients with a short follow-up period; hence results should be interpreted carefully. Nonetheless, it goes with the success of previous reports. To our knowledge, there are no previous reports of using belimumab in monogenic lupus. Therefore, belimumab can be considered as an adjunctive therapeutic option for patients with refractory monogenic SLE. Further follow-up and more patients are needed to confirm this finding and a larger prospective study is required for more definitive conclusions.

**Informed Consent:** Informed consent was obtained from the parents of the patients.

**Peer-review:** Externally peer-reviewed.

**Author Contributions:** Concept - S.M.A.; Design - S.M.A.; Data Collection and/or Processing - L.A.; Analysis and/or Interpretation - L.A.; Literature Search - R.A.; Writing Manuscript - L.A., S.M.A.

**Conflict of Interest:** The authors have no conflict of interest to declare.

**Financial Disclosure:** The authors declared that this study has received no financial support.

## References

- Almlöf J, Nystedt S, Leonard D, Eloranta M, Grosso G, Sjöwall C, et al. Whole-genome sequencing identifies complex contributions to genetic risk by variants in genes causing monogenic systemic lupus erythematosus. *Hum Genet* 2019; 138: 141-50. [Crossref]
- Al-Mayouf SM, Sunker A, Abdwani R, Abrawi S, Almurshedi F, Alhashmi N, et al. Loss-of-function variant in DNASE1L3 causes a familial form of systemic lupus erythematosus. *Nat Genet* 2011; 43: 1186-8. [Crossref]

- Tirosh I, Spielman S, Barel O, Ram R, Stauber T, Paret G, et al. Whole exome sequencing in childhood-onset lupus frequently detects single gene etiologies. *Pediatr Rheumatol Online J* 2019; 17: 52. [Crossref]
- Liphaus B, Caramalho I, Rangel-Santos A, Sliva C, Demengeot J, Carneiro-Sampaio M. LRBA deficiency: A new genetic cause of monogenic lupus. *Ann Rheum Dis* 2020; 79: 427-8. [Crossref]
- Hiraki L, Silverman E. Genomics of systemic lupus erythematosus: Insights gained by studying monogenic young-onset systemic lupus erythematosus. *Rheum Dis Clin North Am* 2017; 43: 415-34. [Crossref]
- Demirkaya E, Sahin S, Romano M, Zhou Q, Ak-sentijevich I. New horizons in the genetic etiology of systemic lupus erythematosus and lupus-like disease: Monogenic lupus and beyond. *J Clin Med* 2020; 9: E712. [Crossref]
- Alperin J, Ortiz-Fernández L, Sawalha A. Monogenic lupus: A developing paradigm of disease. *Front Immunol* 2018; 9: 2496. [Crossref]
- Omarjee O, Picard C, Frchette C, Moreews M, Rieux-Laucat F, Soulas-Sprauel P, et al. Monogenic lupus: Dissecting heterogeneity. *Autoimmun Rev* 2019; 18: 102361. [Crossref]
- Rodero M, Tesser A, Bartok E, Rice G, Della Mina E, Depp M, et al. Type I interferon-mediated autoinflammation due to DNase II deficiency. *Nat Commun* 2017; 8: 2176. [Crossref]
- Smith E, Sen E, Pain C. Diagnosis and treatment of childhood-onset systemic lupus erythematosus (European evidence-based recommendations from the SHARE initiative). *Arch Dis Child Educ Pract Ed* 2019; 104: 259-64. [Crossref]
- Hui-Yuen J, Reddy A, Taylor J, Li X, Eichenfield A, Bermudez L, et al. Safety and efficacy of belimumab to treat systemic lupus erythematosus in academic clinical practices. *J Rheumatol* 2015; 42: 2288-95. [Crossref]
- Ruperto N, Abud-Mendoza C, Viola D, Calvo I, Levy D, Gallegos J, et al. The PLUTO study: Intravenous belimumab in children with systemic lupus erythematosus. *Ann Rheum Dis* 2019; 78(Suppl 2): 764-5. [Crossref]
- Touma Z, Sayani A, Pineau C, Fortin I, Matsos M, Ecker G, et al. Belimumab use, clinical outcomes and glucocorticoid reduction in patients with systemic lupus erythematosus receiving belimumab in clinical practice settings: Results from the OBServe Canada Study. *Rheumatol Int* 2017; 37: 865-73. [Crossref]
- Rodrigues Fonseca A, Felix Rodrigues M, Sztajn-bok F, Gerardin Poirot Land M, Knupp Feitosa de Oliveira S. Comparison among ACR 1997, SLICC and the new EULAR/ACR classification criteria in childhood-onset systemic lupus erythematosus. *Adv Rheumatol* 2019; 59: 20. [Crossref]
- Brunner H, Silverman E, To T, Bombardier C, Feldman B. Risk factors for damage in childhood-onset systemic lupus erythematosus: Cumulative disease activity and medication use predict disease damage. *Arthritis Rheum* 2002; 46: 436-44. [Crossref]
- Macedo A, Isaac L. Systemic lupus erythematosus and deficiencies of early components of the complement classical pathway. *Front Immunol* 2016; 7: 55. [Crossref]

17. Gribbacher B, Warnatz K, Yong P, Korganow A, Peter H. The crossroads of autoimmunity and immunodeficiency: Lessons from polygenic traits and monogenic defects. *J Allergy Clin Immunol* 2016; 137: 3-17. [\[Crossref\]](#)
18. Kim H, Sanchez G, Goldbach-Mansky R. Insights from Mendelian interferonopathies: Comparison of CANDLE, SAVI with AGS, monogenic lupus. *J Mol Med* 2016; 94: 1111-27. [\[Crossref\]](#)
19. Al-Mayouf SM, AlSaleem A, AlMutairi N, AlSobul A, Alzaid T, Alazami A, et al. Monogenic interferonopathies: Phenotypic and genotypic findings of CANDLE syndrome and its overlap with C1q deficient SLE. *Int J Rheum Dis* 2018; 21: 208-13. [\[Crossref\]](#)
20. Ekinci Z, Ozturk K. Systemic lupus erythematosus with C1q deficiency: Treatment with fresh frozen plasma. *Lupus* 2018; 27: 134-8. [\[Crossref\]](#)
21. Olsson R, Hagelberg S, Schiller B, Ringdén O, Truedsson L, Åhlin A. Allogeneic hematopoietic stem cell transplantation in the treatment of human C1q deficiency: The Karolinska experience. *Transplantation* 2016; 100: 1356-62. [\[Crossref\]](#)
22. Basu B, Roy B, Babu B. Efficacy and safety of rituximab in comparison with common induction therapies in pediatric active lupus nephritis. *Pediatr Nephrol* 2017; 32: 1013-21. [\[Crossref\]](#)
23. Bruce IN, Urowitz M, van Vollenhoven R, Aranow C, Fettiplace J, Oldham M, et al. Long-term organ damage accrual and safety in patients with SLE treated with belimumab plus standard of care. *Lupus* 2016; 25: 699-709. [\[Crossref\]](#)
24. Tanaka Y. State-of-the-art treatment of systemic lupus erythematosus. *Int J Rheum Dis* 2020; 23: 465-71. [\[Crossref\]](#)