








# One after another retinal involvement in lupus

Tomoyuki Mutoh<sup>1</sup> , Yuko Shiota<sup>1,2</sup> , Azusa Ito<sup>3</sup> , Hiroshi Fujii<sup>1</sup> , Tomonori Ishii<sup>1</sup> , Toru Nakazawa<sup>3-6</sup> , Hideo Harigae<sup>1</sup> 

A 30-year-old woman was admitted to our hospital because of fever, arthralgia, butterfly erythema, alopecia, and acute deterioration of the right visual acuity, which was 20/1,000 on ophthalmologic examination. She had no history of hypertension or diabetes mellitus. Laboratory findings on admission showed thrombocytopenia (9.9 $\times$ 10<sup>4</sup>/ $\mu$ L) and lymphopenia (580/ $\mu$ L), but abnormal urinalysis and renal dysfunction were not observed. She possessed several autoantibodies, including antinuclear antibody (1:320 with speckled pattern) and anti-Sm antibody (100 U/mL). She was diagnosed with systemic lupus erythematosus (SLE) as she fulfilled the Systemic Lupus International Collaborating Clinics classification criteria (1). Furthermore, funduscopic examination revealed cotton-wool spots, narrowed branch retinal arteries, and retinal hemorrhage in her right eye (Figure 1). These findings were indicative of lupus retinopathy.

#### ORCID iDs of the authors:

T.M. 0000-0001-5995-8609;  
Y.S. 0000-0002-5551-7889;  
A.I. 0000-0002-4956-3432;  
H.F. 0000-0002-6885-6492;  
T.I. 0000-0001-5361-5824;  
T.N. 0000-0002-5591-4155;  
H.H. 0000-0003-4849-7442.

**Cite this article as:** Mutoh T, Shiota Y, Ito A, Fujii H, Ishii T, Nakazawa T, et al. One after another retinal involvement in lupus. *Eur J Rheumatol* 2021; 8(2): 111-2.

<sup>1</sup> Department of Hematology and Rheumatology, Tohoku University Graduate School of Medicine, Sendai, Japan

<sup>2</sup> Department of Hematology and Rheumatology, Tohoku Medical and Pharmaceutical University, Sendai, Japan

<sup>3</sup> Department of Ophthalmology, Tohoku University Graduate School of Medicine, Sendai, Japan

<sup>4</sup> Department of Retinal Disease Control, Tohoku University Graduate School of Medicine, Sendai, Japan

<sup>5</sup> Department of Advanced Ophthalmic Medicine, Tohoku University Graduate School of Medicine, Sendai, Japan

<sup>6</sup> Department of Ophthalmic Imaging and Information Analytics, Tohoku University Graduate School of Medicine, Sendai, Japan

#### Address for Correspondence:

Tomoyuki Mutoh; Department of Hematology and Rheumatology, Tohoku University Graduate School of Medicine, Sendai, Japan

E-mail: qma-kyo@hotmail.co.jp

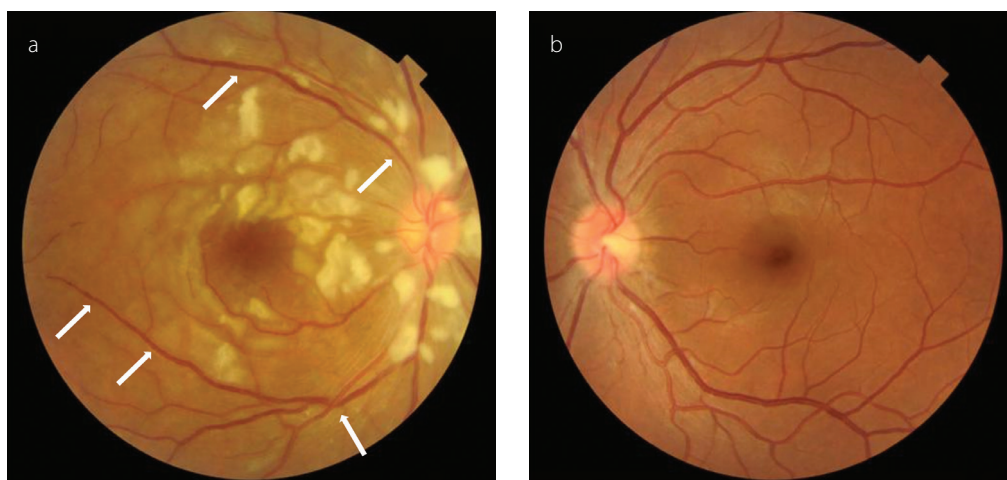
Submitted: January 23, 2020

Accepted: May 09, 2020

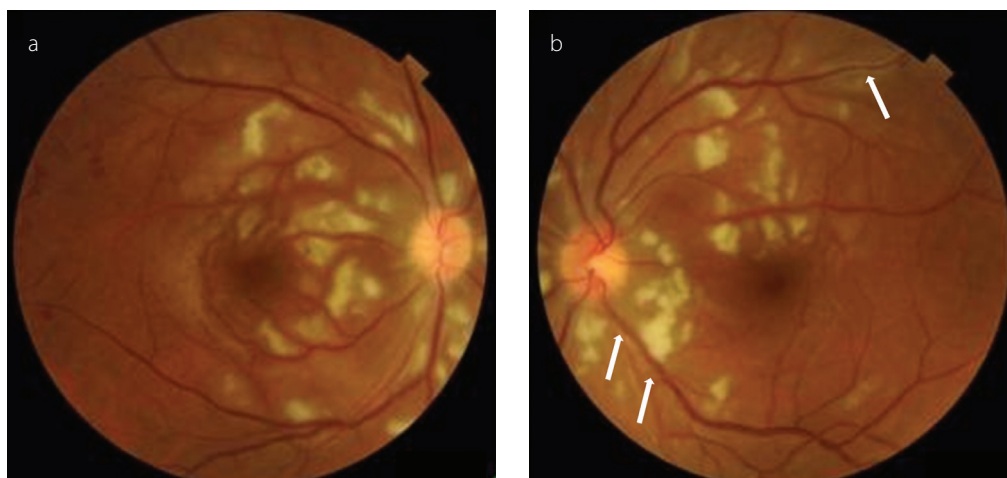
Available Online Date: September 3, 2020

Copyright@Author(s) - Available online at [www.eurjrheumatol.org](http://www.eurjrheumatol.org).

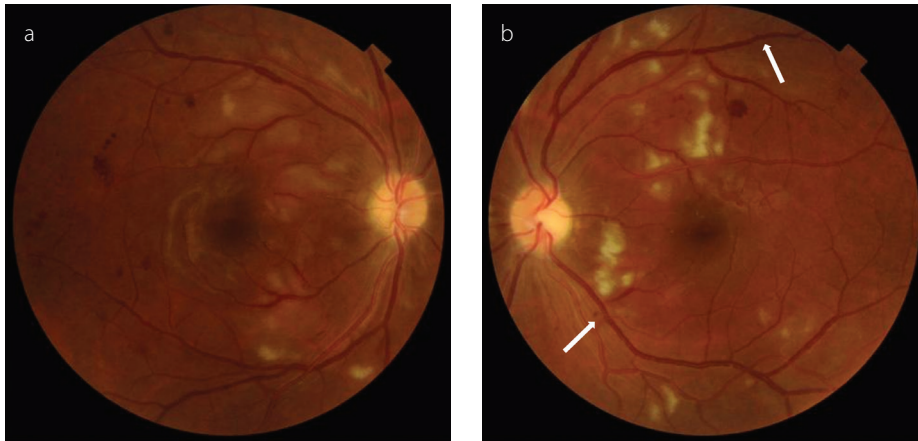
Content of this journal is licensed under a Creative Commons Attribution-NonCommercial 4.0 International License.



**Figure 1. a, b.** Fundus examination shows cotton-wool spots, narrowed branch retinal arteries (arrows), and retinal hemorrhage in the right eye (a), and no lesions in the left eye (b).



**Figure 2. a, b.** Fundus examination (a: right eye, b: left eye) shows increased cotton-wool spots and narrowed branch retinal arteries (arrows) in the left eye 1 month after the first methylprednisolone pulse therapy.



**Figure 3. a, b.** Fundus examination (a: right eye, b: left eye) shows improved cotton-wool spots and narrowed branch retinal arteries (arrows) in both retinæ 2 months after the intravenous administration of cyclophosphamide.

She was treated with methylprednisolone (mPSL) pulse therapy (1,000 mg/day for 3 days) followed by 60 mg of oral prednisolone (PSL), and her right vision showed significant improvement (20/40) on day 28 from admission. However, she rapidly developed left visual impairment (20/50), and her visual acuity of the right eye slightly worsened (20/50) 1 month after the initiation of immunosuppressive therapy, and cotton-wool spots were observed similarly in her left eye (Figure 2). We initiated treatment with 1,000 mg of mycophenolate mofetil (MMF) twice daily to inhibit further disease progression, but it did not sufficiently improve her visual disturbance. After discontinuation of MMF, we administered intravenous cyclophosphamide (IVCY) (500 mg, monthly) with concurrent second mPSL pulse therapy (1,000 mg/day for 3 days), because we judged that immunosuppression with PSL and MMF was insufficient to control the disease activity of SLE. After 2 months, funduscopic findings (Figure 3) had dramatically improved. Her both visual acuities were also almost recovered (20/25) at day 90, and she was discharged. She

was subsequently treated in our outpatient department for 12 months, and PSL dose could be tapered to 7 mg/day without recurrence of the ocular lesions.

Lupus retinopathy is a potentially vision-threatening complication, which develops in up to 29% of the patients with SLE with active systemic disease (2). In most cases, it is not the initial manifestation; however, in this case, acute deterioration of the visual acuity was one of the first presentations at the time of SLE onset. Therefore, it is important to evaluate the ocular lesions carefully as SLE might cause severe damage to the organs. In addition, the presence of retinopathy is usually suggestive of high disease activity (3). Notably, this patient developed lupus retinopathy particularly in the left eye even after treatment with high dose of PSL, which was successfully treated with mPSL pulse therapy followed by IVCY. This clinical course indicates that lupus retinopathy might occur in the normal eye even after the initiation of induction therapy for SLE unless the disease activity is well controlled, because retinopathy

can mostly occur in the activity phase of SLE (4). Accordingly, in patients with SLE complicated by severe retinopathy, early intervention with potent immunosuppressants, including IVCY, should be considered to prevent lupus retinopathy-induced permanent loss of vision.

**Informed Consent:** Written informed consent was obtained from the patient.

**Peer-review:** Externally peer-reviewed.

**Author Contributions:** Concept - T.M., Y.S.; Design - T.M., Y.S.; Supervision - Y.S., H.F., T.I., T.N., H.H.; Data Collection and/or Processing - T.M., A.I.; Analysis and/or Interpretation - T.M., A.I.; Literature Search - T.M., Y.S.; Writing Manuscript - T.M., Y.S.; Critical Review - Y.S., H.F., T.I., T.N., H.H.

**Acknowledgements:** The authors thank Dr. Tsuyoshi Shirai for intellectual advice.

**Conflict of Interest:** The authors have no conflict of interest to declare.

**Financial Disclosure:** The authors declared that this study has received no financial support.

## References

- Petri M, Orbai AM, Alarcon GS, Gordon C, Merrill JT, Fortin PR, et al. Derivation and validation of the Systemic Lupus International Collaborating Clinics classification criteria for systemic lupus erythematosus. *Arthritis Rheum* 2012; 64: 2677-86. [\[Crossref\]](#)
- Palejwala NV, Walia HS, Yeh S. Ocular manifestations of systemic lupus erythematosus: A review of the literature. *Autoimmune Dis* 2012; 2012: 290898. [\[Crossref\]](#)
- Ushiyama O, Ushiyama K, Koarada S, Tada Y, Suzuki N, Ohta A, et al. Retinal disease in patients with systemic lupus erythematosus. *Ann Rheum Dis* 2000; 59: 705-8. [\[Crossref\]](#)
- Dammacco R. Systemic lupus erythematosus and ocular involvement: An overview. *Clin Exp Med* 2018; 18: 135-49. [\[Crossref\]](#)