

Transient osteoporosis of the hip

Joe Thomas¹ , Kurian Ninan² 

A 31-year-old male presented with pain in the right hip on activity which had persisted for the last 2 weeks. He denied any other joint pain and did not have any other co-morbid illness. On examination, range of hip movements was found to be painful in all directions. His investigation revealed normal acute phase reactants. Magnetic resonance imaging (MRI) revealed diffuse T2w-hyperintense signal in the head and neck of the right femur which is consistent with marrow edema (Figure 1a). No fracture or collapse of the femoral head or joint effusion was observed. These changes were consistent with transient osteoporosis of hip joint. Patient was advised conservative treatment and his symptoms completely subsided within 4 weeks. Follow-up MRI performed 2 months later showed complete resolution of the marrow edema in the right femoral head and no residual subarticular bone changes were observed (Figure 1b). The transient osteoporosis of hip (TOH) is an idiopathic and self-limiting disorder which is characterized by unexplained hip pain and was first reported by Ravault (1947) followed by Curtiss and Kincaid in 1959 (1). The TOH has been reported more frequently in healthy middle-aged males with a male: female ratio of 3:1 (2). The etiopathogenesis of TOH may include microvascular injury, nontraumatic reflex sympathetic dystrophy, metabolic factors, viral infection, neurological factors, and endocrine factors (3). An MRI is a sensitive test for diagnosing TOH and was described first in the radiology literature by Bloem (4). TOH is a self-limiting disease, a symptomatic and supportive treatment is recommended, and TOH should be included in the list of differential diagnoses of acute onset of hip pain.

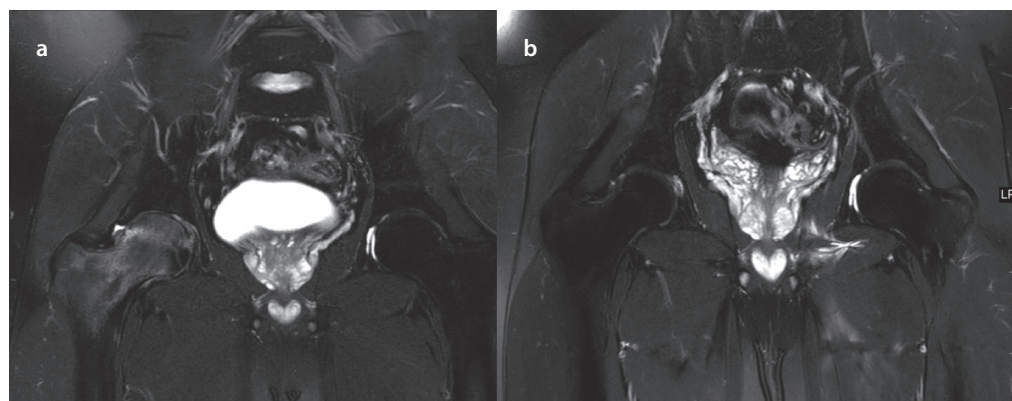


Figure 1. a, b. Magnetic resonance imaging (MRI) showing diffuse T2w hyperintense signal involving the head and neck of the right femur which is in keeping with marrow edema (a); complete resolution of the marrow edema in the right femoral head and no residual subarticular bone changes (b)

Informed Consent: Written informed consent was obtained from the patient who participated in this study.

Peer-review: Externally peer-reviewed.

Author Contributions: Concept - J.T., K.N.; Design - J.T., K.N.; Supervision - J.T., K.N.; Materials - J.T., K.N.; Data Collection and/or Processing - J.T., K.N.; Analysis and/or Interpretation - J.T., K.N.; Literature Search - J.T., K.N.; Writing Manuscript - J.T., K.N.; Critical Review - J.T., K.N.

Conflict of Interest: The authors have no conflict of interest to declare.

Financial Disclosure: The authors declared that this study has received no financial support.

References

1. Curtiss PH Jr, Kincaid WE. Transitory demineralization of the hip in pregnancy. A report of three cases. *J Bone Joint Surg Am* 1959; 41: 1327-33. [\[CrossRef\]](#)
2. Hadidy AM, Al Ryalat NT, Hadidi ST, Tarawneh ES, Hadidi MT, Samara OA, et al. Male transient hip osteoporosis: Are physicians at a higher risk? *Arch Osteoporos* 2009; 4: 41-5.
3. Harrington S. Idiopathic TOH. *Phys Sportsmed* 2000; 28: 34.
4. Bloem JL. Transient osteoporosis of the hip: MR imaging. *Radiology* 1988; 167: 753-5. [\[CrossRef\]](#)

ORCID IDs of the authors:

J.T. 0000-0001-7255-6356;
K.N. 0000-0001-7062-743X.

Cite this article as: Thomas J, Ninan K. Transient osteoporosis of the hip. *Eur J Rheumatol* 2019; 6(2): 110.

¹Department of Orthopaedics & Rheumatology, Aster Medcity, Kerala, India

²Department of Radiology, Aster Medcity, Kerala, India

Address for Correspondence:
Joe Thomas, Department of Orthopaedics & Rheumatology, Aster Medcity, Kerala, India

E-mail: joethomasmd@yahoo.co.in

Submitted: 15 April 2018
Accepted: 7 June 2018
Available Online Date: 08.10.2018

Copyright@Author(s) - Available online at www.eurjrheumatol.org.

Content of this journal is licensed under a Creative Commons Attribution-NonCommercial 4.0 International License.

