

Fever with multiple large vessel aneurysms: An unusual presentation of Takayasu arteritis in a child

Ashish Agarwal¹, Ankur K. Jindal¹, Sandesh Guleria¹, Tarun K. Jain², Bhagwant R. Mittal², Deepti Suri¹ 

A 12-year-old boy presented with a history of fever for one and a half months. On performing an examination, he had pulse rate of 90/min, respiratory rate of 20/min, and blood pressure of 110/70 mmHg; all peripheral pulses were equally palpable, pallor was noticed, and a bruit was heard in the bilateral carotid region. Examinations of the eyes revealed unremarkable findings. Laboratory investigations revealed anemia, a high erythrocyte sedimentation rate, and elevated C-reactive protein levels; work-up for infective causes was negative (Table 1). Doppler ultrasound revealed thickening of the internal lamina of the left common carotid artery, dilatation (1.2 cm), and a small saccular outpouching (8 mm) of the superior mesenteric artery (SMA) near its origin. Contrast-enhanced computed tomography angiography of the abdominal vessels revealed diffuse irregular and non-calcified mural thickening, vascular dilatation, and multiple small saccular aneurysms involving the abdominal aorta, proximal SMA, and proximal parts of the bilateral renal arteries (Figure 1, 2). Computed tomography and corresponding fluorodeoxyglucose positron emission tomography images revealed mural thickening of the proximal left subclavian artery, brachiocephalic artery, dilated abdominal aorta, bilateral proximal renal arteries, and proximal SMA (Figure 3-6). The boy was diagnosed as having Takayasu arteritis (TA) based on the European League Against Rheumatism / Paediatric Rheumatology International Trials Organisation / Paediatric Rheumatology European Society classification criteria for childhood TA (1). He was initiated on injections of methylprednisolone (30 mg/kg/day) that led to prompt defervescence. He was given five pulse doses of methylprednisolone and was subsequently initiated on oral prednisolone (2 mg/kg/day). He was



ORCID ID of the corresponding author:
D.S. 0000-0001-5009-8761.

Cite this article as: Agarwal A, Jindal AK, Guleria S, Jain TK, Mittal BR, Suri D. Fever with multiple large vessel aneurysms: An unusual presentation of Takayasu arteritis in a child. *Eur J Rheumatol* 2018; 5: 287-8.

¹ Allergy Immunology Unit, Department of Pediatrics, Advanced Pediatrics Center, Post Graduate Institute of Medical Education and Research, Chandigarh, India

² Department of Nuclear Medicine, Post Graduate Institute of Medical Education and Research, Chandigarh, India

Address for Correspondence:

Deepti Suri, Allergy Immunology Unit, Department of Pediatrics, Advanced Pediatrics Center, Post Graduate Institute of Medical Education and Research, Chandigarh, India

E-mail: surideepti@gmail.com

Submitted: 19 September 2017

Accepted: 21 December 2017

Available Online Date: 2 April 2018

Copyright©Author(s) - Available online at www.eurjrheumatol.org.

Content of this journal is licensed under a Creative Commons Attribution-NonCommercial 4.0 International License.



Table 1. Laboratory investigations

Investigation	Result
Hemoglobin level (gm/L)	84
White blood cell count ($\times 10^9$ cells/L)	91.8
Differential count (N/L/M/E)	82/10/04/03
Platelet counts ($\times 10^9$ /L)	142
ESR (mm in the 1st hour)	79
CRP (mg/L) (N < 6)	86
Tuberculin skin test	0 mm
Blood culture	
Urine culture	Sterile
Sterile	
Serum Widal titers	Non-reactive
IgM EBV-VCA	Non-reactive
HIV serology	Non-reactive
HBsAg, Anti-HCV	Non-reactive
VDRL test	Non-reactive
2-dimensional echocardiography	Normal

CRP: C-reactive protein; EBV-VCA: Epstein Barr Virus-viral capsid antigen; ESR: erythrocyte sedimentation rate; HBsAg: hepatitis B surface antigen; HCV: hepatitis C virus; HIV: human immunodeficiency virus; N/L/M/E: neutrophils/lymphocytes/monocytes/eosinophils; VDRL: venereal disease research laboratory

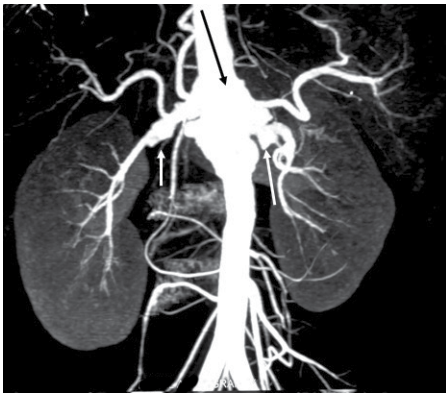


Figure 1. Contrast-enhanced computed tomography of the abdominal vessels shows dilatation of the abdominal aorta near the origin of the proximal superior mesenteric artery (black arrow) and small saccular aneurysms at the proximal parts of the bilateral renal arteries (white arrow)

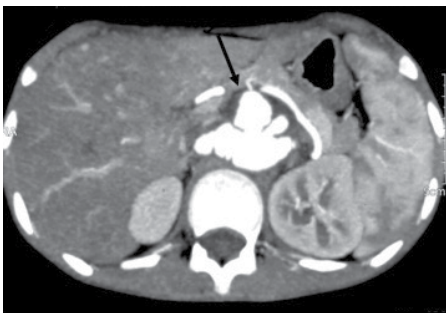


Figure 2. Transverse cuts of contrast enhanced computed tomography of the abdominal vessels show multiple aneurysms at the origin of the renal arteries (arrow)

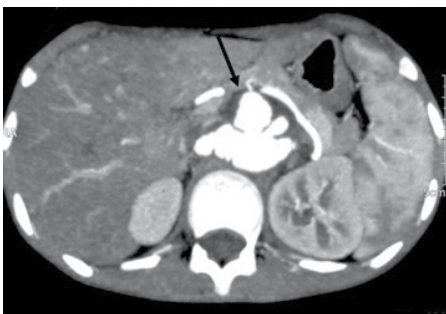


Figure 3. Fluorodeoxyglucose (FDG) positron emission tomography images at the thoracic level show FDG uptake (SUVmax: 1.9) at the thickened wall of the dilated brachiocephalic artery

also initiated on monthly pulse cyclophosphamide (500 mg/m², total of six pulses). During his follow-up visits for the last 8 months, he continued to be afebrile; the bruit in the carotid region disappeared, blood pressure was normal, and all pulses were equally palpable. At present, he is on tapering doses of prednisolone and azathioprine (2 mg/kg/day).

Takayasu arteritis is a chronic inflammatory disease of the aorta and its major branches. The nat-

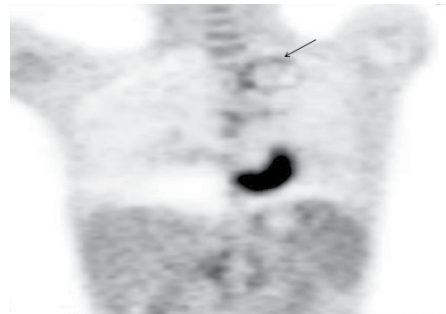


Figure 4. Fluorodeoxyglucose (FDG) positron emission tomography images show FDG uptake (SUVmax: 1.5) at the thickened wall of the dilated left subclavian artery




Figure 5. Fluorodeoxyglucose (FDG) positron emission tomography trans-axial images at the abdominal level show FDG uptake at the thickened wall of the dilated abdominal aorta and superior mesenteric artery [SUVmax: 2.8 at the abdominal aorta (arrow) and 2.2 at the superior mesenteric artery]

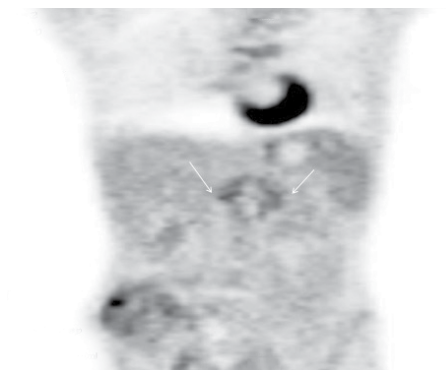


Figure 6. Fluorodeoxyglucose (FDG) positron emission tomography coronal images at the abdominal level show FDG uptake (SUVmax: 1.9) at the thickened wall of the proximal renal arteries

ural course of Takayasu arteritis consists of two phases: an initial acute phase that represents the phase of inflammation, resulting in constitutional symptoms, and a second phase of vascular insufficiency, leading to symptoms such as claudication and diminished pulses. Studies on pediatric TA cases from India and USA have reported that hypertension and headache are the most common presenting manifestations (2-4). The index case had fever as the sole clinical presentation and had no signs of vascular insufficiency.

Fever has been reported in approximately 4-45% of children with TA; however, fever as the only clinical presentation of TA in children is extremely uncommon (2-4).

Stenosis of large vessels is the most common angiographic abnormality associated with TA (5). Aneurysms have been reported in approximately 19-65% of children with TA (6). Aneurysms as the only angiographic abnormality of TA without stenosis or occlusion are extremely uncommon (7-8).

Informed Consent: Written informed consent was obtained from parents of the patients who participated in this study.

Peer-review: Externally peer-reviewed.

Author Contributions: Concept - A.A., A.K.J., S.G.; Design - A.A., A.K.J., S.G.; Supervision - A.A., A.K.J., S.G., D.S.; Data Collection and Processing - A.A., A.K.J., S.G., D.S.; Analysis and/or Interpretation - A.A., A.K.J., S.G., D.S., T.K.J., B.R.M.; Literature Search - A.A., A.K.J., S.G., D.S., T.K.J., B.R.M.; Writing Manuscript - A.A., A.K.J., S.G., D.S., T.K.J., B.R.M.; Critical Review - A.A., A.K.J., S.G., D.S., T.K.J., B.R.M.

Conflict of Interest: The authors have no conflict of interest to declare.

Financial Disclosure: The authors declared that this study has received no financial support.

REFERENCES

- Ozen S, Pistorio A, Iusan SM, Bakkaloglu A, Herlin T, Brik R, et al. EULAR/PRINTO/PRES criteria for Henoch-Schönlein purpura, childhood polyarteritis nodosa, childhood Wegener granulomatosis and childhood Takayasu arteritis: Ankara 2008. Part II: Final classification criteria. *Ann Rheum Dis* 2010; 69: 798-806. [CrossRef]
- Jain S, Sharma N, Singh S, Bali HK, Kumar L, Sharma BK. Takayasu arteritis in children and young Indians. *Int J Cardiol* 2000; 75: 153-57. [CrossRef]
- Goel R, Kumar TS, Danda D, Joseph G, Jeyaseelan V, Surin AK, et al. Childhood-onset Takayasu arteritis-experience from a tertiary care center in South India. *J Rheumatol* 2014; 41: 1183-89. [CrossRef]
- Brunner J, Feldman BM, Tyrrell PN, Kuemmerle-Deschner JB, Zimmerhackl LB, Gassner I, et al. Takayasu arteritis in children and adolescents. *Rheumatol Oxf Engl* 2010; 49: 1806-14. [CrossRef]
- Jain S, Kumari S, Ganguly NK, Sharma BK. Current status of Takayasu arteritis in India. *Int J Cardiol* 1996; 54: 111-16. [CrossRef]
- McCulloch M, Andronikou S, Goddard E, Sinclair P, Lawrenson J, Mandelstam S, et al. Angiographic features of 26 children with Takayasu's arteritis. *Pediatr Radiol* 2003; 33: 230-35. [CrossRef]
- Halaweish I, Patel H, Si M-S. Giant aortic aneurysm in a child with Takayasu arteritis. *Cardiol Young* 2016; 26: 593-95. [CrossRef]
- Hooda A, Kunwar B. Takayasu arteritis presenting as multiple arch vessel aneurysms. *Heart Asia* 2013; 5: 84. [CrossRef]