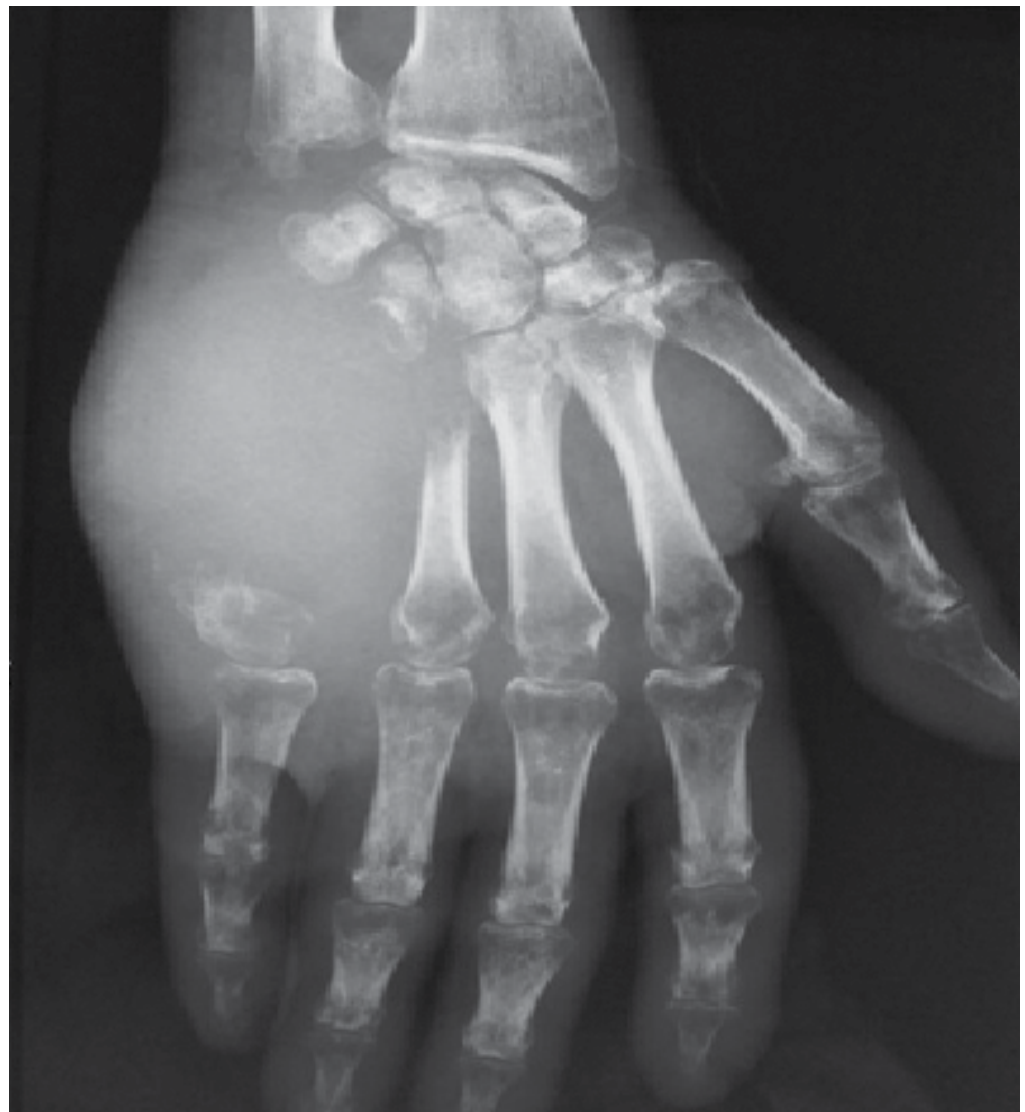

# Acrometastasis as the first manifestation of lung carcinoma

Mohammed El Idrissi<sup>1</sup>, Nessrine Akasbi<sup>2</sup>, Abdelhalim Elibrahimi<sup>1</sup>, Abdelmajid Elmrini<sup>1</sup>

A 68-year-old male smoker presented with a painful mass on his right hand since the past 3 months. The mass, which mimicked an infectious, inflammatory, or metabolic disease, was swollen, erythematous, and located on the dorsum of his right hand. X-ray images of his hands revealed a massive and aggressive osteolytic lesion with cortical expansion, that destroys the fifth metacarpal (Figure 1). According to the patient's radiological features, the diagnosis of a malignant tumor was strongly considered. Bony biopsy was performed, and a histopathological examination found a moderately differentiated carcinoma infiltrating the bone. Immunohistochemistry study results were negative for thyroid transcription factor-1, cytokeratin 20, prostatic-specific antigen, and thyroglobulin. The radiological findings and anatomopathological features highlighted the need to find an underlying malignant lesion in our patient. A thoraco-abdomino-pelvic computed tomography scan was performed, which revealed a right lobe lung mass (Figure 2). Biopsy of the lung tumor revealed adenocarcinoma. The patient was finally diagnosed as having lung carcinoma with acrometastasis. For that, he received palliative chemotherapy.



Cite this article as: El Idrissi M, Akasbi N, Elibrahimi A, Elmrini A. Acrometastasis as the first manifestation of lung carcinoma. *Eur J Rheumatol* 2018; 5(3): 212-3.

<sup>1</sup> Department of Orthopedic Surgery, Centre Hospitalier Universitaire Hassan II, Fez, Morocco

<sup>2</sup> Department of Rheumatology, Centre Hospitalier Universitaire Hassan II, Fez, Morocco

*Address for Correspondence:*  
Mohammed El Idrissi, Department of Orthopedic Surgery, Centre Hospitalier Universitaire Hassan II, Fez, Morocco

E-mail: elidrimed@gmail.com

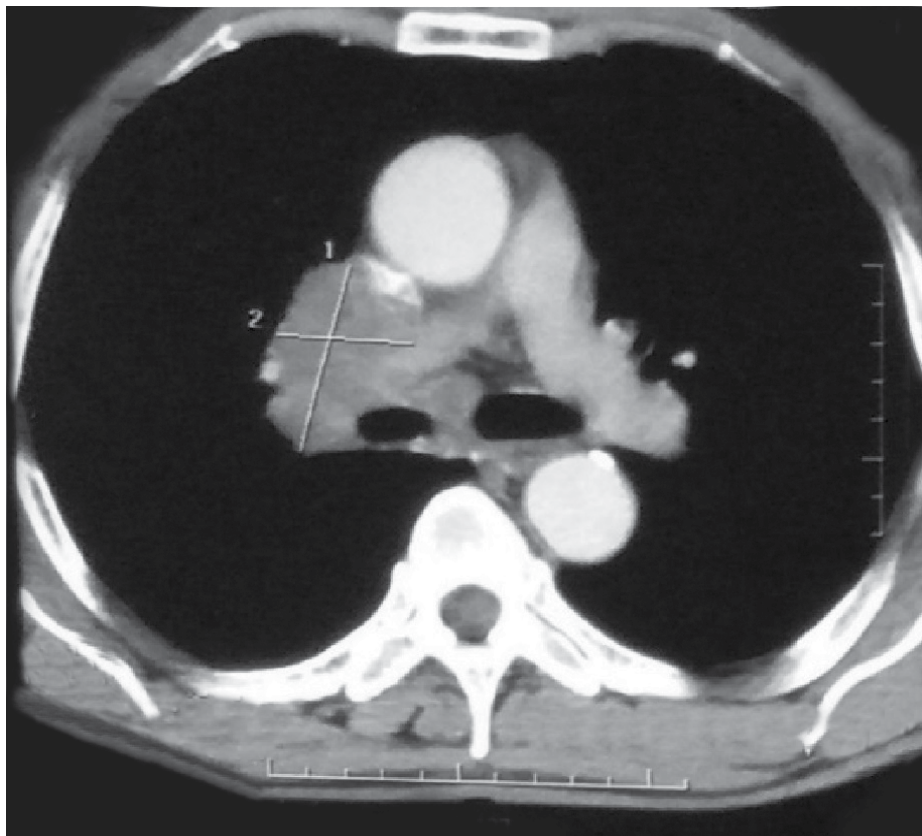
Submitted: 5 April 2017

Accepted: 20 May 2017

Available Online Date: 07 December 2017

©Copyright by 2018 Medical Research and Education Association - Available online at [www.eurjrheumatol.org](http://www.eurjrheumatol.org).

**Figure 1.** Aggressive osteolytic lesion with cortical expansion, which amputated the fifth metacarpal



**Figure 2.** Thoraco-abdomino-pelvic computed tomography scan: a right lobe lung mass

The occurrence of acrometastasis is very rare. Only 1% to 3% cases of metastases occur in the hands (1). Moreover, acrometastasis as the first manifestation of carcinoma is very rare. Metastases in the hands preferentially reach the phalanges and then the metacarpals and carpals (2). Acrometastasis is most commonly observed secondary to lung cancer (40%-50%) (3). It is associated with a poor prognosis. Phys-

iopathological mechanisms of acrometastasis are not well elucidated. The principal theory is the ability of tumor cells to migrate and invade the bone matrices of the hands under the influence of proinflammatory cytokines such as tumor necrosis factor, interleukin 6, and osteoclast-activating factors. Usually, acrometastasis presentations mimic an infectious, an inflammatory, or a metabolic disease. For this reason,

its diagnosis is often delayed (4). The present case illustrates a rare and exceptional situation of acrometastasis of the metacarpals as the first manifestation of lung cancer.

**Peer-review:** Externally peer-reviewed.

**Author Contributions:** Concept - M.E., N.A.; Design - M.E., N.A.; Supervision - A.E., A. Elmrini; Resources - M.E., N.A.; Materials - M.E., N.A.; Data Collection and/or Processing - M.E., N.A.; Analysis and/or Interpretation - M.E., N.A.; Literature Search - M.E., N.A.; Writing Manuscript - M.E., N.A.; Critical Review - A.E., A. Elmrini.

**Conflict of Interest:** The authors have no conflict of interest to declare.

**Financial Disclosure:** The authors declared that this study has received no financial support.

## References

1. Kanbay A, Oguzulgen KI, Ozturk C, Memis L, Demircan S, Kurkcuoglu C, et al. Malignant pleural mesothelioma with scalp, cerebellar, and finger metastases: a rare case. *South Med J* 2007; 100: 63-65. [\[CrossRef\]](#)
2. Flynn CJ, Danjoux C, Wong J, Christakis M, Rubenstein J, Yee A, et al. Two cases of acrometastasis to the hands and review of the literature. *Current Oncology* 2008; 15: 51-58.
3. Sahoo TK, Das SK, Majumdar SK, Senapati SN, Parida DK. Digital <https://doi.org/10.7860/jcdr/2016/16063.7951> [\[CrossRef\]](#)
4. Long LS, Brickner L, Helfend L, Wong T, Kubota D. Lung Cancer Presenting as Acrometastasis to the Finger: A Case Report. *Case Rep Med* 2010; 2010: Article ID 234289.