

# Gouty tophi with purpura in a patient with ischemic heart disease and acute kidney injury

Manoj Karbhari Pawar

A 77-year-old male with a history of chronic poorly controlled hypertension (HTN) and ischemic heart disease (IHD) was referred to a dermatologist for the presence of red-brownish flat lesions over both forearms and the dorsum of hands since 2 weeks and localized yellowish elevated lesions that were hard in consistency over both 1<sup>st</sup> and 2<sup>nd</sup> toes and the left little finger since 8 months; these were associated with moderate-grade pain. The patient was on tablet nebivolol (5 mg) (Nebicip 5; Cipla, Mumbai, India) once daily and tablet clopidogrel (75 mg) plus aspirin (75 mg) (Clasprin; Biocon, Mumbai, India) for HTN and IHD. He had been admitted under the care of an internist for cellulitis of the left foot with acute kidney injury (AKI) 10 days previously. He was a chronic alcoholic and tobacco chewer. Skin examination revealed multiple purpuric lesions of varying sizes over both forearms and the dorsum of hands (Figure 1) along with multiple subcutaneous gouty tophi over both 1<sup>st</sup> toes and the left little finger (Figure 2, 3). On close inspection, there was extrusion of gouty material from the right great toe (Figure 4). Findings of the remaining cutaneous examination were unremarkable. Laboratory evaluation revealed leukocytosis with neutrophilia and elevated serum creatinine (2.3 mg/dL), urea (59 mg/dL), and uric acid (10 mg/dL) levels. The prothrombin time was also increased (16.5 s). Based on these findings, the patient was diagnosed as having gout with purpura co-existing with left foot cellulitis and AKI. X-ray of the right foot showed osteolysis with a coarse trabecular pattern, while that of the left forearm was normal (Figure 5). His chest X-ray revealed cardiomegaly with blunting of the left cardiopulmonary angle (Figure 6).

Gout is one of the most common debilitating types of arthritis, mostly present in males and postmenopausal females; it is characterized by increased serum uric acid levels (more than 6.8 mg/dL at 37°C, pH 7.4) and the deposition of monosodium urate crystals in and around the joints (1, 2). If this hyperuricemic stage persists for a long duration without treatment, gouty tophi develop and get deposited around joints, particularly the 1<sup>st</sup> metatarsophalangeal joint (podagra), and eventually damage the involved joint (1, 2). As most uric acid gets excreted through the kidney, any renal insufficiency that predisposes the patient to the development of gout and chronic hyperuricemia can also cause renal injury (1). Because our patient was suffering from chronic HTN, he was likely to have some degree of renal impairment, which was further worsened by preuremic (cellulitis-induced) AKI, leading to the development and aggravation of gout. Because the patient was taking anticoagulants, he developed iatrogenic purpuric lesions, which were possibly worsened by AKI and alcoholism (3). The gold standard for the diagnosis of gout is the identification

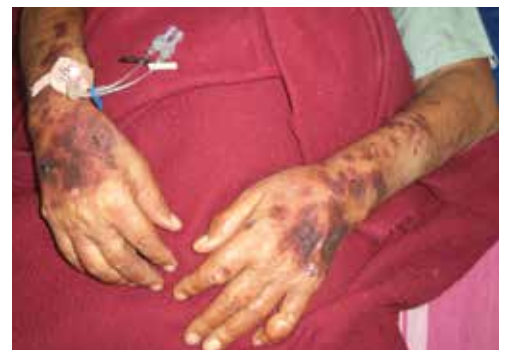

Figure 1. Purpuric lesions over both forearms

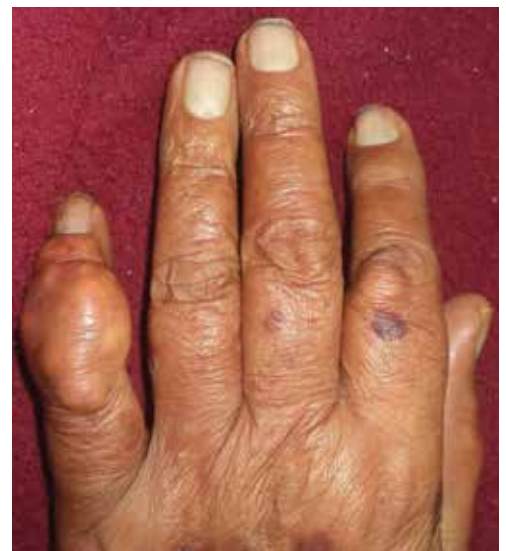

Figure 2. Gouty tophi over left little finger



**Cite this article as:** Pawar, MK. Gouty tophi with purpura in a patient with ischemic heart disease and acute kidney injury. *Eur J Rheumatol* 2018; *Eur J Rheumatol* 2018; 5: 149-50.

Department of Dermatology, Private Practice, Maharashtra, India

*Address for Correspondence:*  
Manoj Karbhari Pawar, Department of Dermatology, Private Practice, Maharashtra, India

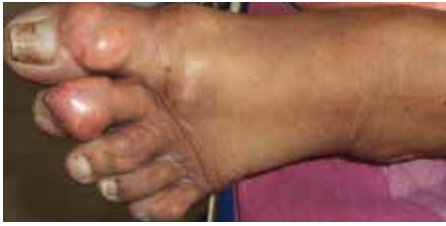E-mail: manojpawar624@yahoo.com

Submitted: 28 December 2016

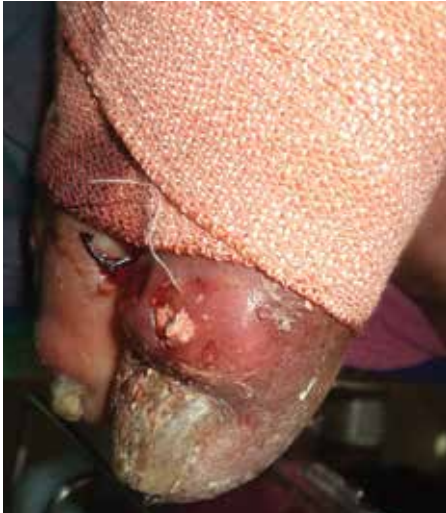Accepted: 30 March 2017

Available Online Date: 25 October 2017

©Copyright by 2018 Medical Research and Education Association - Available online at [www.eurjrheumatol.org](http://www.eurjrheumatol.org).

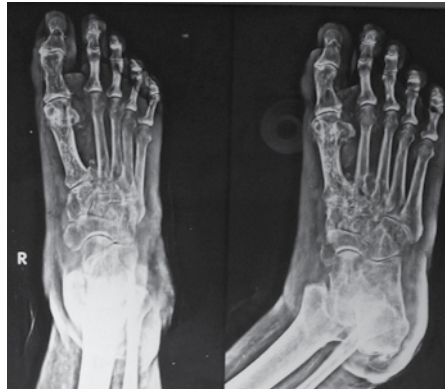

**Figure 3.** Podagra of left foot and gout tophi over left 2<sup>nd</sup> and 3<sup>rd</sup> toe

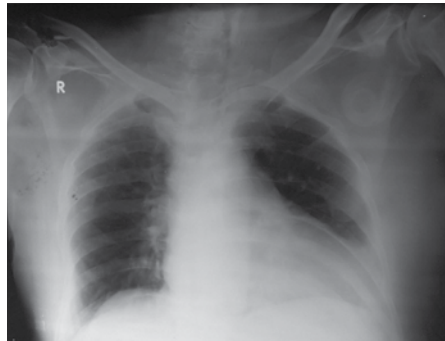


**Figure 4.** Extrusion of gouty material from lesion over right great toe

of urate crystals in the tissue and/or synovial fluid of an inflamed joint (1). Patients presenting with gout often have co-morbidities such as hypertension, obesity, diabetes, chronic kid-



**Figure 5.** X-ray of right foot showing osteolysis with trabecular pattern



**Figure 6.** Chest X-ray showing cardiomegaly with blunting of left cardiopulmonary angle

ney disease, and IHD (1). The treatment of gout varies from the stage of the disease and level of uric acid. Acute flares are treated with nonsteroidal anti-inflammatory agents, colchicines,

and steroids. Allopurinol, febuxostat, uricosuric drugs, and uricases reduce uric acid levels (1). Lifestyle modifications and concurrent management of co-morbidities help in treating gout and achieving remission.

**Informed Consent:** Written informed consent was obtained from patient who participated in this study.

**Peer-review:** Externally peer-reviewed.

**Author Contributions:** Concept - P.M.K.; Design - P.M.K.; Supervision - P.M.K.; Resources - P.M.K.; Materials - P.M.K.; Data Collection and/or Processing - P.M.K.; Analysis and/or Interpretation - P.M.K.; Literature Search - P.M.K.; Writing Manuscript - P.M.K.; Critical Review - P.M.K.

**Conflict of Interest:** The author have no conflict of interest to declare.

**Financial Disclosure:** The author declared that this study has received no financial support.

## References

1. Bitik B, M. Akif Öztürk. An old disease with new insights: Update on diagnosis and treatment of gout. *Eur J Rheumatol* 2014; 1: 72-7.
2. Tausche AK, Wunderlich C, Aringer M. Tophaceous gout and renal insufficiency: A new solution for an old therapeutic dilemma. *Case Rep Med* 2011; 2011: 397646.
3. Tsuda T, Okamoto Y, Sakaguchi R, Katayama N, Hara I, Hayashi H, et al. Purpura due to aspirin-induced platelet dysfunction aggravated by drinking alcohol. *J Int Med Res* 2001; 29: 374-80.