

Sternoclavicular joint arthritis as the initial presentation of sarcoidosis

Vikas Gupta¹ , Durga Prasanna Misra¹ , Namita Mohindra² , Niraj Kumari³ , Vikas Agarwal¹ 

Abstract

Sarcoidosis is a multisystem granulomatous disease of unknown etiology. It can affect the musculoskeletal system in the form of acute and rarely, in the form of chronic peripheral arthritis involving bilateral small and large joints. Axial joint involvement with sarcoidosis is rare. Herein we report a case with sternoclavicular joint arthritis as the initial presentation of sarcoidosis. This report aims to demonstrate a rare initial presentation of sarcoidosis and highlight the importance of considering sarcoidosis as a differential diagnosis in patients presenting with sternoclavicular joint arthritis.

Keywords: Sternoclavicular joint, sarcoidosis, arthritis, musculoskeletal abnormalities

Introduction

Sarcoidosis is a systemic inflammatory disease of unknown etiology characterized by the presence of non-caseating granulomas in affected tissues. The lung is the most affected organ; however, virtually any organ can be involved, including the musculoskeletal system. Musculoskeletal involvement usually occurs in the form of acute, self-limited polyarthritis, observed in up to 40% patients, whereas chronic or recurrent sarcoidosis is rarely observed, affecting only 1%–4% patients (1, 2). Arthritis in sarcoidosis is usually peripheral, affecting bilateral small and large joints in a symmetrical fashion, whereas axial skeleton involvement is rare (3, 4). We report on a middle-aged female with sternoclavicular joint arthritis as her initial presentation of sarcoidosis. This presentation is very unique and unusual for sarcoidosis. We present this case to highlight the importance of considering sarcoidosis as a differential diagnosis of sternoclavicular joint arthritis in addition to infections, rheumatoid arthritis, and spondyloarthropathy.

Case Presentation

A 45-year-old female presented with a history of pain and swelling in the right sternoclavicular joint for 2 months followed by pain in the bilateral shoulder, elbow, metacarpophalangeal (MCP), proximal interphalangeal (PIP), knee, and ankle joints 15 days later. She also complained of anorexia, malaise, and fatigue for the same duration. Examination revealed a swollen and tender right sternoclavicular joint and tender bilateral shoulder, elbow, wrist, MCP, PIP, knee, and ankle joints. She had non-tender, non-erythematous subcutaneous nodules over bilateral thighs, calves, and shins. Other systemic examination was normal. A plain radiograph of the right sternoclavicular joint was normal; however, ultrasound showed mild effusion and grade 2 power Doppler signals suggesting active synovitis. She had an increased erythrocyte sedimentation rate (52 mm in the 1st hour) and serum C-reactive protein levels (5.43 mg/dL; normal <0.6 mg/dL) and negative HLA-B27, rheumatoid factor, and anti-citrullinated peptide antibodies. Tuberculosis and sarcoidosis were considered as differential diagnosis. Tuberculin skin test was 5 mm; computed tomography (CT) of the thorax revealed interlobular septal thickening, bilateral hilar and mediastinal lymphadenopathy, and mosaic attenuation of the lungs. Sternoclavicular arthritis was evident on CT of the thorax (Figure 1). Further work-up revealed hypercalciuria (24 h calcium excretion, 396 mg/day) and high normal serum calcium levels (10.1 mg/dL). Antinuclear antibody (ANA) and extractable nuclear antigen screenings were negative, and the anti-double stranded DNA level was <10 IU/mL. Serum angiotensin-converting enzyme levels were increased (58 U/L, N=8–53 U/L). 99m technetium methylene diphosphonate bone scintigraphy did not reveal any sacroiliac joint involvement.

Biopsy from the subcutaneous nodule showed septal panniculitis with tiny granulomas negative for acid-fast bacilli (AFB) by Ziehl-Neelsen staining (Figure 2). Transbronchial lung biopsy revealed well-formed



ORCID IDs of the authors:

V.G. 0000-0002-2089-027X,
D.P.M. 0000-0002-5035-7396,
N.M. 0000-0003-3043-1218,
N.K. 0000-0002-9221-9581,
V.A. 0000-0002-4508-1233.

Cite this article as: Gupta V, Misra DP, Mohindra N, Kumari N, Agarwal V. Sternoclavicular joint arthritis as the initial presentation of Sarcoidosis. Eur J Rheumatol 2018; 5: 142-4.

¹Department of Clinical Immunology, Sanjay Gandhi Postgraduate Institute of Medical Sciences, Lucknow, Uttar Pradesh, India

²Department of Radiodiagnosis, Sanjay Gandhi Postgraduate Institute of Medical Sciences, Lucknow, Uttar Pradesh, India

³Department of Pathology, Sanjay Gandhi Postgraduate Institute of Medical Sciences, Lucknow, Uttar Pradesh, India

Address for Correspondence:
Vikas Gupta, Department of Clinical Immunology, Sanjay Gandhi Postgraduate Institute of Medical Sciences, Lucknow, Uttar Pradesh, India

E-mail: vikasgcapri@yahoo.co.in

Submitted: 2 August 2017

Accepted: 24 August 2017

Available Online Date: 22 January 2018

©Copyright by 2018 Medical Research and Education Association - Available online at www.eurjrheumatol.org.

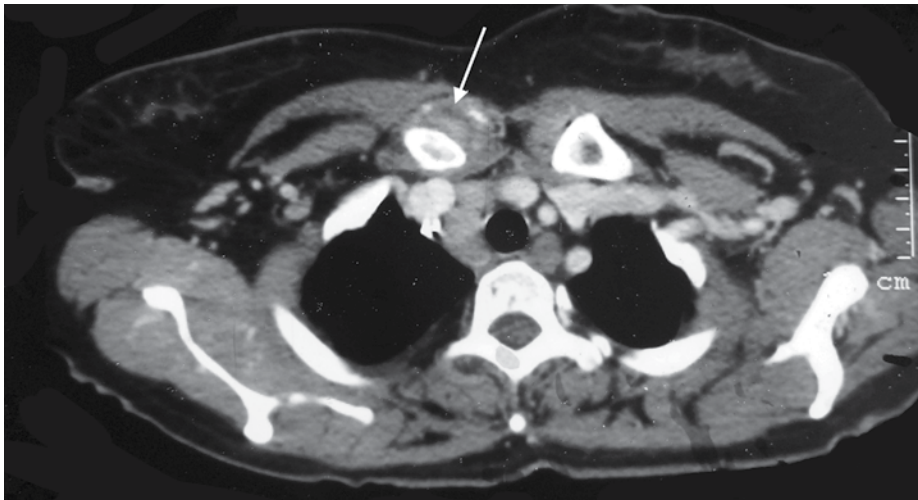


Figure 1. Axial contrast-enhanced CT of the thorax showing increased thickness of the soft tissue around the medial end of the right clavicle (arrow) compared with the left clavicle

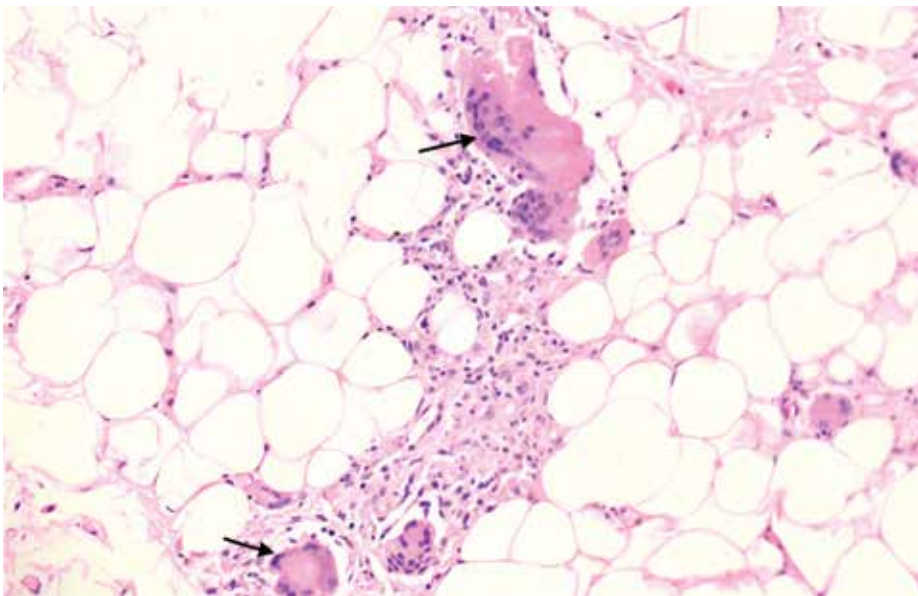


Figure 2. Skin biopsy showing septal panniculitis with multiple tiny granulomas (arrows)

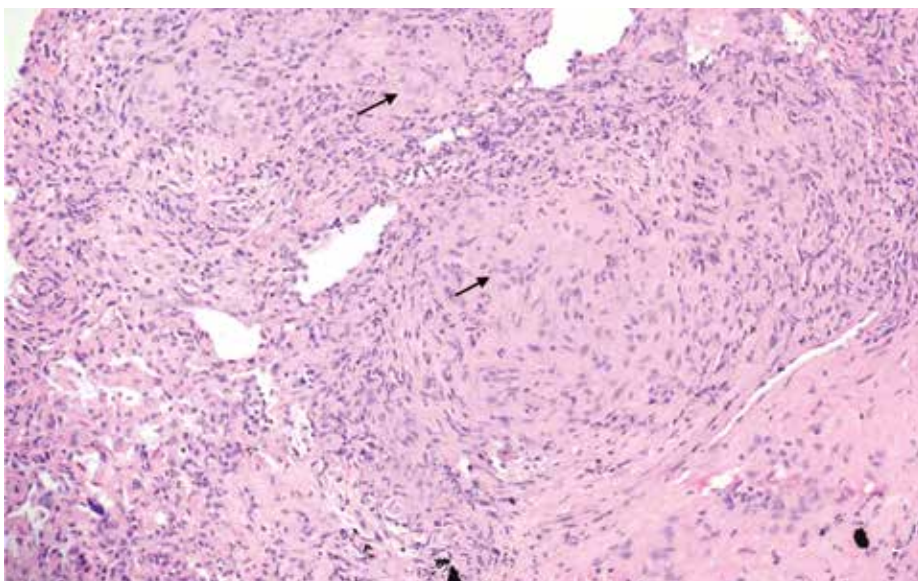


Figure 3. Lung biopsy showing multiple non-caseating well-formed granulomas (arrows)

granulomas negative for AFB (Figure 3). With these findings of mediastinal lymphadenopathy, non-caseating granuloma on the skin, lung biopsy negative for AFB, and hypercalciuria, sarcoidosis was diagnosed. She was started on oral steroids, hydroxychloroquine, and methotrexate and showed improvement with therapy at 3 months.

Discussion

Acute arthritis occurs in up to 40% patients with sarcoidosis and can be the presenting manifestation, usually as a part of Löfgren syndrome (a triad of acute arthritis, bilateral hilar adenopathy, and erythema nodosum) (1, 2, 5). With the exception of Löfgren syndrome, joint manifestations are rarely observed at symptom onset in sarcoidosis (6). Acute arthritis in Löfgren syndrome is usually oligoarticular, can be polyarticular or rarely, monoarticular (3, 5, 7). Ankle joint involvement is the most frequent in acute sarcoid arthritis, followed by knee, wrist, and metacarpophalangeal joint involvement (3, 8). Axial joint, including costochondral and chondrosternal joints, involvement and sacroiliitis is rare in sarcoidosis (3, 4, 8). However, sternoclavicular joint involvement, to the best of our knowledge, has never been described in sarcoid arthropathy. Here we highlight that sternoclavicular joint can be involved in acute sarcoid arthritis and can be the initial manifestation of sarcoidosis.

Sternoclavicular joint involvement has been reported in 1%-41% patients with rheumatoid arthritis, 2%-28% patients with ankylosing spondylitis, 15% patients with psoriatic arthritis, and rarely in reactive arthritis (9). Our patient did not have any clinical features to suggest any of these diagnoses and after work-up, the diagnosis of sarcoidosis was confirmed. The sternoclavicular joint can be involved because of infectious arthritis in sarcoidosis as these patients are at an increased risk of opportunistic infections because of the use of immunosuppressive therapy (10, 11). However, the presence of sternoclavicular arthritis at the onset followed by polyarticular involvement a few days later and no prior use of immunosuppressive therapy make septic arthritis unlikely in our patient. Moreover, the patient's arthritis improved with corticosteroids and disease-modifying antirheumatic drugs, thereby underscoring the fact that sternoclavicular joint involvement was indeed a part of sarcoid arthropathy. Our report highlights sternoclavicular joint involvement in sarcoid arthropathy as a presenting manifestation, emphasizing the need to consider sarcoidosis as a differential diagnosis in a patient with sternoclavicular joint involvement.

Informed Consent: Written informed consent was obtained from the patient who participated in this study.

Peer-review: Externally peer-reviewed.

Author Contributions: Concept - V.G., V.A.; Design - V.G., V.A.; Supervision - D.M., V.A.; Resources - None; Materials - None; Data Collection and/or Processing - V.G., N.M., N.K., V.A.; Analysis and/ or Interpretation - V.G., D.M., N.M., N.K., V.A.; Literature Search - V.G., D.M.; Writing Manuscript - V.G., D.M.

Conflict of Interest: The authors have no conflict of interest to declare.

Financial Disclosure: The authors declared that this study has received no financial support.

References

1. Sharma SK, Soneja M, Sharma A, Sharma MC, Hari S. Rare manifestations of sarcoidosis in modern era of new diagnostic tools. *Indian J Med Res* 2012; 135: 621-9.
2. Zisman DA, Shorr AF, Lynch JP 3rd. Sarcoidosis involving the musculoskeletal system. *Semin Respir Crit Care Med* 2002; 23: 555-70. [\[CrossRef\]](#)
3. Sweiss N, Patterson K, Sawaqed R, Jabbar U, Korsten P, Hogarth K, et al. Rheumatologic Manifestations of Sarcoidosis. *Semin Respir Crit Care Med* 2010; 31: 463-73. [\[CrossRef\]](#)
4. Ungprasert P, Crowson CS, Matteson EL. Clinical Characteristics of Sarcoid Arthropathy: A Population-Based Study. *Arthritis Care Res* 2016; 68: 695-9. [\[CrossRef\]](#)
5. Torralba KD, Quismorio FP Jr. Sarcoidosis and the rheumatologist. *Curr Opin Rheumatol* 2009; 21: 62-70. [\[CrossRef\]](#)
6. Nessrine A, Zahra A, Taoufik H. Musculoskeletal involvement in sarcoidosis. *J Bras Pneumol* 2014; 40: 175-82. [\[CrossRef\]](#)
7. Kirresh O, Schofield J, George G. Acute sarcoidosis: Löfgren's syndrome. *Br J Hosp Med* 2015; 76: 154-8. [\[CrossRef\]](#)
8. Kobak S. Sarcoidosis: a rheumatologist's perspective. *Ther Adv Musculoskelet Dis* 2015; 7: 196-205. [\[CrossRef\]](#)
9. Taccari E, Spadaro A, Ricciari V, Guerrisi R, Guerrisi V, Zoppini A. Sternoclavicular joint disease in psoriatic arthritis. *Ann Rheum Dis* 1992; 51: 372-4. [\[CrossRef\]](#)
10. Geller DS, Pope JB, Thornhill BA, Dorfman HD. Cryptococcal pyarthrosis and sarcoidosis. *Skeletal Radiol* 2009; 38: 721-7. [\[CrossRef\]](#)
11. Ross JJ, Katz JD. Cryptococcal meningitis and sarcoidosis. *Scand J Infect Dis* 2002; 34: 937-9. [\[CrossRef\]](#)