

Tropical pyomyositis caused by *Klebsiella pneumoniae* with rheumatoid arthritis

Juliana Brandão Pinto Carneiro¹, Taíssa Pinto de Souza¹, Mauro Martins Lippi²,
Felipe Augusto Silva Gama³, Helena Lúcia Alves Pereira¹, Sandra Lúcia Euzébio Ribeiro¹

The patient, a 33-year-old woman with rheumatoid arthritis, presented with a 3-month history of a painful nodule in the right thigh that progressively evolved to a large mass, accompanied by intermittent fever. Physical examination revealed a large fluctuating mass involving the entire anterior portion of the right thigh, which was tender and warm to palpation (Figure 1). Her medications included methotrexate 25 mg/week, prednisone 10 mg/day, [Infliximab 4mg/kg 6/6week] (total duration of treatment, 3 years). Laboratory tests revealed the following: hemoglobin 11.7 g/dL, white blood cell count $21.16 \times 10^3/\mu\text{L}$ with 85% neutrophils and 7% band cells, erythrocyte sedimentation rate 100 mm/h, and C-reactive protein level 15 mg/dL (normal <0.8 mg/dL). Blood culture was negative; Human Immunodeficiency Virus (HIV) and hepatitis serologies were non-reactive. Magnetic resonance imaging (MRI) of the right thigh revealed voluminous liquid collection involving the entire anterior compartment of the thigh with complete quadriceps musculature destruction (Figure 2, 3). A high volume of purulent material was drained after surgical incision of the abscess region, followed by necrotic muscle tissue debridement. Cultures from the abscess material and biopsy specimens of the muscles revealed *Klebsiella pneumoniae* with a multi-susceptible profile. Findings of fungal and mycobacterial tests were negative. Muscle biopsy showed abscedated nonspecific chronic myositis. Antibiotic treatment was initiated with imipenem for 14 days with a good clinical response. Tropical pyomyositis caused by gram-negative bacteria is uncommon and primarily seen in immunocompromised patients, being identified in only 11% of patients according to an American meta-analysis (1-3). The diagnosis may be difficult, particularly when we are faced with an atypical clinical case, such as this patient.



ORCID IDs of the authors:

J.B.P.C. 0000-0001-7184-0582;
T.P.S. 0000-0002-3176-544X;
M.M.L. 0000-0003-4716-0207;
F.A.S.G. 0000-0001-6766-4424;
H.L.A.P. 0000-0002-2437-5355;
S.L.E.R. 0000-0002-4777-8659.

Cite this article as: Pinto Carneiro JB, de Souza TP, Lippi MM, Silva Gama FA, Alves Pereira HL, Euzébio Ribeiro SL. Tropical pyomyositis caused by *Klebsiella pneumoniae* with rheumatoid arthritis. Eur J Rheumatol 2018; 5: 83-4.

¹ Department of Rheumatology, Getúlio Vargas University Hospital (HUGV), Federal University of Amazon School of Medicine (UFAM), Manaus, Brazil

² Department of Intensive Care, Getúlio Vargas University Hospital (HUGV), Federal University of Amazon School of Medicine (UFAM), Manaus, Brazil

³ Department of Radiology, Getúlio Vargas University Hospital (HUGV), Federal University of Amazon School of Medicine (UFAM), Manaus, Brazil

Address for Correspondence:

Juliana Brandão Pinto Carneiro,
Department of Rheumatology, Getúlio Vargas University Hospital (HUGV),
Federal University of Amazon School of Medicine (UFAM), Manaus, Brazil

E-mail: jubrandao_@hotmail.com

Submitted: 28 December 2016

Accepted: 5 March 2017

Available Online Date: 4 July 2017

©Copyright by 2018 Medical Research and Education Association - Available online at www.eurjrheumatol.org.

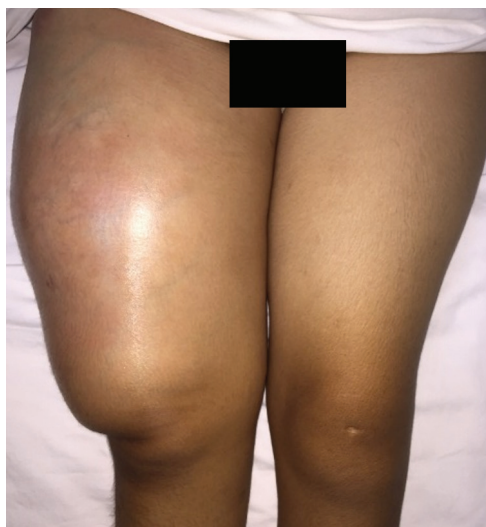


Figure 1. Large fluctuating mass involving anterior portion of the right thigh in all of its extension, intact skin presenting a shining erythematous aspect with collateral circulation

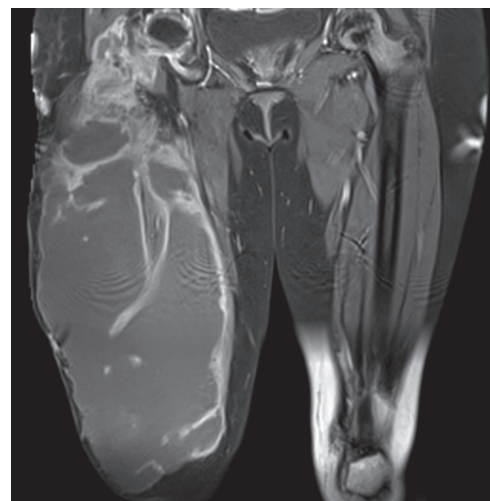


Figure 2. Axial T1-weighted magnetic resonance imaging (MRI) of right thigh revealed voluminous liquid collection involving all anterior compartment of the thigh with complete quadriceps musculature destruction

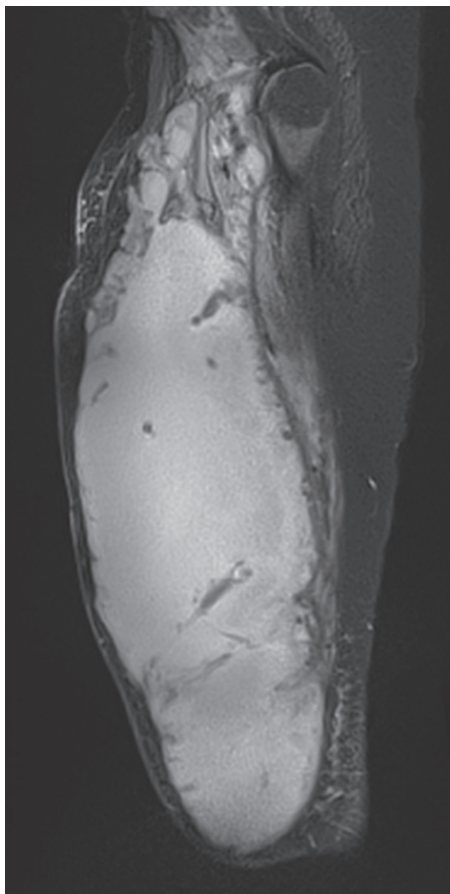


Figure 3. Sagittal T2-weighted MRI revealed the same liquid collection from the root of anterior thigh to the inferior limit of the right knee

Peer-review: Externally peer-reviewed.

Author Contributions: Concept - J.C., T.S., S.R.; Design - J.C., T.S., F.G., S.R.; Supervision - J.C., T.S., M.L., F.G., H.P., S.R.; Resources - J.C., T.S., S.R.; Materials - J.C., T.S., F.G., S.R.; Data Collection and/or Processing - J.C., T.S., M.L., F.G., H.P., S.R.; Analysis and/or Interpretation - J.C., T.S., M.L., F.G., S.R.; Literature Search - J.C., T.S.; Writing Manuscript - J.C., T.S., M.L., F.G., H.P., S.R.; Critical Review - J.C., T.S., M.L., F.G., H.P., S.R.

Conflict of Interest: No conflict of interest was declared by the authors.

Financial Disclosure: The authors declared that this study has received no financial support.

References

1. Christin L, Sarosi GA. Pyomyositis in North America: case reports and review. *Clin Infect Dis* 1992; 15: 668-77. [\[CrossRef\]](#)
2. Chauhan, S, Jain, S, Varma, S, Chauhan SS. Tropical pyomyositis (myositis tropicans): current perspective. *Postgrad Med J* 2004; 80: 267-70. [\[CrossRef\]](#)
3. Crum NF. Bacterial pyomyositis in the United States. *Am J Med* 2004; 117: 420-8. [\[CrossRef\]](#)