

A clinical threat in patients with granulomatosis polyangiitis in remission: Subglottic stenosis

Yunus Ugan¹, Atalay Doğru¹ , Giray Aynalı², Mehmet Şahin¹, Şevket Ercan Tunç¹ 

Abstract

Granulomatosis with polyangiitis (GPA) is a systemic necrotizing granulomatous disease that involves small- and medium-sized arteries and affects the main respiratory tracts and kidneys. Upper respiratory tract involvement usually occurs in 90% of patients, who most frequently present with symptoms of chronic sinusitis. Subglottic stenosis (SS) is a rare and severe complication that is usually observed in approximately 15% of patients. Here we present a case of SS in a patient with limited form of GPA during remission.

Keywords: Granulomatosis with polyangiitis, subglottic stenosis, rituximab

Introduction

Granulomatosis with polyangiitis (GPA) (Wegener's granulomatosis) is a systemic necrotizing disease that involves the main upper and lower respiratory tracts and results in pauci-immune glomerulonephritis in the kidneys and areas supplied by small- and medium-sized arteries (1). If the disease is localized only to the upper respiratory tract or lungs, it is defined as a limited form and constitutes one-fourth of cases. Some of these cases may then progress to the systemic form (2).

Subglottic stenosis (SS) occurs in patients as a result of active disease or chronic recurrent inflammation. It is a life-threatening complication, although it occurs less frequently (about 15%) than other upper respiratory tract complications (3). It generally occurs as a late finding of the disease. Stenosis is usually localized in the subglottic region and the upper part of the trachea. However, it may extend to the lower trachea and bronchi (4). Exertional dyspnea and stridor are clinically most common in patients with SS development. Tracheostomy is performed according to the degree of stenosis in some patients who fail to respond to treatment. Here we describe a case of SS in a patient with limited form of GPA during remission.

Case Presentation

The patient was a 40-year-old female presenting with recurrent attacks of chronic sinusitis and otitis attacks for nearly 4 years. Based on the patient's complaints, a decrease in hearing in the left ear was detected 2 years previously, and a tube was inserted in the left ear. One year previously, destruction of the framework of the nose and nasal septum perforation occurred (Figure 1), and biopsy was performed by an otolaryngologist due to the chronic inflammation. As a result of the biopsy, the patient was diagnosed with granulomatous inflammation and was directed to the rheumatology clinic. The patient presented with weakness, fatigue, weight loss (10 kg in last 6 months), shortness of breath due to upper airway obstruction, arthralgia in the hand joints, and continuous discharge in the eyes as a result of lacrimal duct obstruction. During the physical examination, no hemoptysis and urine discoloration were found, blood pressure (BP) was 110/70 mmHg, body temperature was 36.4°C, conjunctiva were pale, there was saddle nose deformity on the face, and rhonchi were heard on respiratory auscultation. Laboratory tests revealed the following: WBC: $8.1 \times 10^3 \mu\text{L}$, Hb: 9.8 g/dL, MCV: 72 fL, plt: $546 \times 10^3 \mu\text{L}$, C-reactive protein: 5.7 mg/L (N: 0-3), erythrocyte sedimentation rate: 63 mm/h, creatinine: 0.9 mg/dL. Urine microscopic findings were normal; protein was not detected in urine, and immunological tests demonstrated positive anti-nuclear cytoplasmic antibody (c-ANCA) (against proteinase 3). In the patient's thoracic computed tomography (CT), 3-4 pieces of patchy infiltrative self-healing lesions, which were 4x2.5 cm in diameter and were surrounded by ground-glass opaque areas, were observed in the middle and upper lobe of the right lung. In nasal endoscopy, common hyperemia, edema, and secretions were found in the mucosa. The patient was diagnosed with limited-form GPA on the basis of biopsy, clinical, and laboratory findings. She was treated with intravenous methyl prednisolone at a dose of 1 mg/kg/day and cyclophosphamide



ORCID IDs of the authors:
A.D. 0000-0002-9797-1182;
Ş.E.T. 0000-0002-1221-0131.

Cite this article as: Ugan Y, Doğru A, Aynalı G, Şahin M, Tunç ŞE. A clinical threat in patients with granulomatosis polyangiitis in remission: Subglottic stenosis. Eur J Rheumatol 2018; 5: 69-71.

¹ Division of Rheumatology, Department of Internal Medicine, Süleyman Demirel University School of Medicine, Isparta, Turkey

² Department of Otorhinolaryngology, Süleyman Demirel University School of Medicine, Isparta, Turkey

Address for Correspondence:
Division of Rheumatology, Department of Internal Medicine, Süleyman Demirel University School of Medicine, Isparta, Turkey

E-mail: dryunusugan@hotmail.com

Submitted: 30 arch 2016

Accepted: 30 May 2016

Available Online Date: 11 April 2017

©Copyright by 2018 Medical Research and Education Association - Available online at www.eurjrheumatol.org.

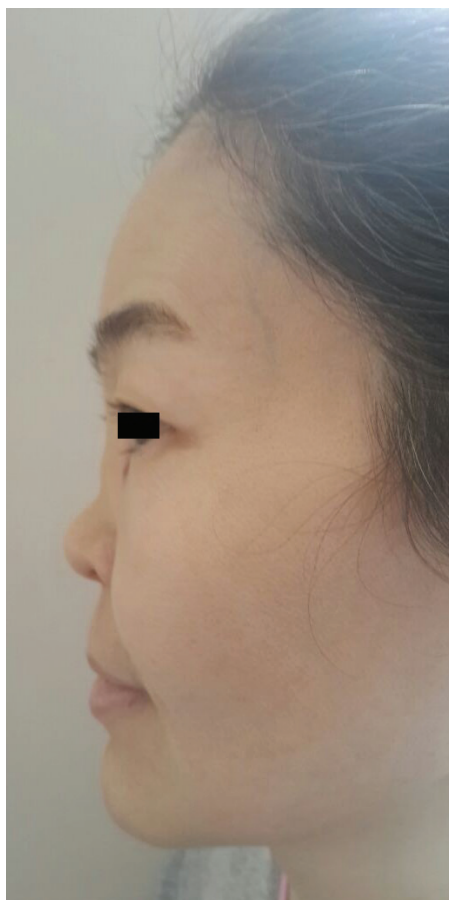


Figure 1. Saddle nose deformity in the patient

(Endoxan; EIP Eczacıbası, Germany) at a dose of 750 mg/m² and trimethoprim/sulfamethoxazole (Bactrim; DEVA, Turkey) at a dose of 800/160 mg on alternate days. Steroid dosage was tapered slowly. At the end of 6 months, the patient's clinical symptoms completely resolved; in addition, the lesions in the lung also resolved on control thoracic CT. Nasal endoscopy revealed that mucosal hyperemia and edema completely regressed (Figure 2). The patient was admitted with hoarseness that persisted for longer than 1 week and newly developed stridor. Results for acute-phase reactants (CRP and ESR), urinalysis, and chest radiography were within normal limits. However, constriction was observed in the subglottic region in the laryngoscopy performed by the otolaryngologist (Figure 3).

The cause of stenosis was considered as cicatrix or local inflammatory activity. A literature search was performed. Surgery, rituximab, and pulse steroid were planned as methods of treatment. Steroid treatment of intravenous methyl prednisolone at 1 g/day for 3 days and rituximab at 375 mg/m²/week (Mabthera, Roche, Switzerland) for a period of 4 weeks was administered to the patient. Tracheostomy was performed by the otolaryngologist for the

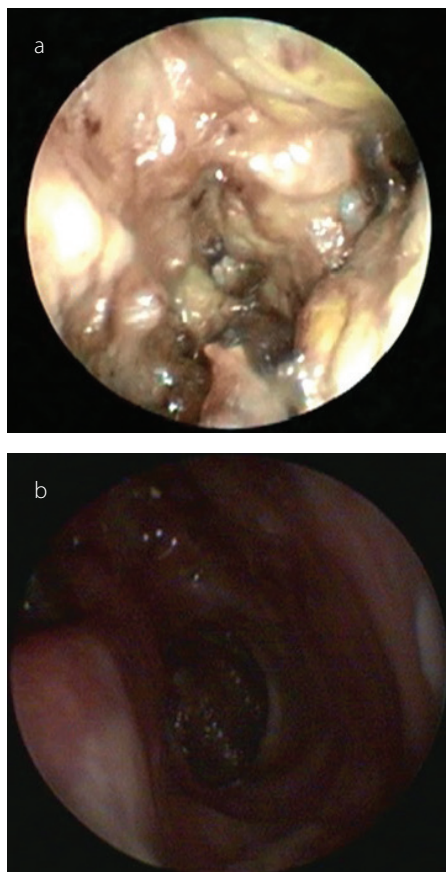


Figure 2. a, b. Pre-treatment (a) and post-treatment (b) appearance of the nasal mucosa with nasal endoscopy

patient who had severe breathing difficulties despite the treatment. Subglottic surgery was performed. Histological examination of the surgical material revealed fibrosis. Post-surgery, shortness of breath and hoarseness improved, and the tracheostomy tube was removed. Clinical symptoms remained absent for 2 months, after which hoarseness recurred and tracheostomy was re-performed. The patient was followed with tracheostomy. Informed consent was obtained from the patient.

Discussion

Wegener's granulomatosis is a relatively rare, gender independent disease, which progresses with granuloma formation and necrotizing vasculitis. ANCA is noted to play a role in its pathogenesis. Its limited form, which is known as being localized to the upper respiratory tract and lung, is usually used to characterize the conditions in which there is no severe disease, and it is not accompanied by ANCA-associated alveolar hemorrhage and kidney involvement (5). Chronic sinusitis is most commonly seen in upper respiratory tract complications, the clinical diagnosis of which is delayed with long-term antibiotic therapy, as seen in our patient. On tissue biopsy, the granulation tissue is observed; the gold

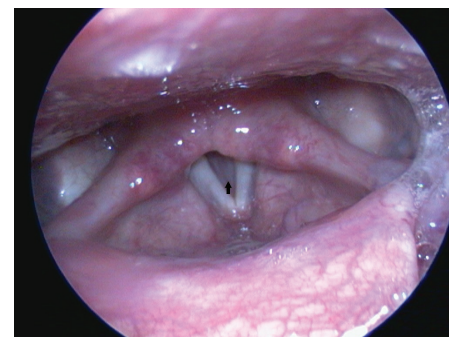


Figure 3. Subglottic stenosis appearance with flexible laryngoscope (black arrow)

standard method of diagnosis. Tissue granulation on biopsy, however, it is not necessary for patients who are clinically and serologically considered as having GPA.

Radiologically, a finding of 34% is encountered in the lung, and bilateral nodular infiltrates, single nodule, cavitations, and alveolar hemorrhage are most commonly observed (2). Our patient had no hemoptysis, and new findings were detected on chest X-ray; thus, alveolar hemorrhage was not considered. Patchy infiltrates were however detected in the right lung during pulmonary imaging.

Subglottic stenosis is a common tracheo-bronchial complication of GPA and occurs in approximately 15% of patients. It can be the first and only symptom of the disease despite being very rare (4). Patients generally complain about voice alteration, dyspnea on exertion, and progressively increasing stridor. In the subglottic region, a fragile and erythematous mucosa, ulceration, and sometimes, accompanying granulation tissue lead to stenosis. Findings indicative of active diseases such as ulceration, cobblestone appearance in the mucosa, and pseudotumor formation can be observed in the tracheobronchial involvement of GPA. Stenosis and cicatricial lesions can also be observed at the end of the healing process in some cases (6). Medical and interventional treatment options are applied in the treatment. Interventional treatments include corticosteroid injections into the lesion, dilatation, carbon dioxide laser, and stent and resection-reanastomosis applications. GK, cyclophosphamide, and rituximab treatments are recommended as medical treatments. A higher rate of remission has been reported in treatments in which rituximab is administered than in those in which cyclophosphamide is administered (7). Our patient was treated with rituximab as SS developed during cyclophosphamide treatment; however, an adequate clinical response could not be achieved, which mandated open tracheostomy.

In conclusion, SS development in patients with GPA occurs independently of the severity of the disease. Therefore, it should be considered that SS, which is life-threatening and plays an important role in morbidity, may show progressive development even in the remission period.

Informed Consent: Written informed consent was obtained from the patient who participated in this study.

Peer-review: Externally peer-reviewed.

Author Contributions: Concept - Y.U., A.D.; Design - Y.U., A.D.; Supervision - M.Ş, S.E.T.; Materials - Y.U., A.D. G.A.; Data Collection and/or Processing - A.D., Y.U., G.A.; Analysis and/or Interpretation - Y.U., A.D.; Writer - A.D., M.Ş, S.E.T.; Critical Review - M.Ş, S.E.T.

Conflict of Interest: No conflict of interest was declared by the authors.

Financial Disclosure: The authors declared that this study has received no financial support.

References

1. Falk RJ, Gross WL, Guillevin L, Hoffman GS, Jayne DR, Jennette JC, et al. Granulomatosis with polyangiitis (Wegener's): an alternative name for Wegener's granulomatosis. *Arthritis Rheum* 2011; 63: 863-4. [\[CrossRef\]](#)
2. Lally L, Spiera RF. Pulmonary vasculitis. *Rheum Dis Clin North Am* 2015; 41: 315-31. [\[CrossRef\]](#)
3. Martinez Del Pero M, Rasmussen N, Chaudhry A, Jani P, Jayne D. Structured clinical assessment of the ear nose and throat in patients with granulomatosis with polyangiitis (Wegener's). *Eur Arch Otorhinolaryngol* 2013; 270: 345-54. [\[CrossRef\]](#)
4. Solans-Laqué , Bosch-Gil J, Canela M, Lorente J, Pallisa E, Vilardell-Tarrés M. Clinical features and therapeutic management of subglottic stenosis in patients with Wegener's granulomatosis. *Lupus* 2008; 17: 832-6. [\[CrossRef\]](#)
5. WGET Research Group. Design of the Wegener's Granulomatosis Etanercept Trial (WGET). *Control Clin Trials* 2002; 23: 450-68. [\[CrossRef\]](#)
6. Gluth M, Shinnars P, Kasperbauer J. Subglottic stenosis associated with Wegener's granulomatosis. *Laryngoscope* 2003; 113: 1304-7. [\[CrossRef\]](#)
7. Girard C, Charles P, Terrier B, Bussonne G, Cohen P, Pagnoux C, et al. Tracheobronchial stenoses in granulomatosis with polyangiitis (Wegener's): A report on 26 cases. *Medicine (Baltimore)* 2015; 94: e1088. [\[CrossRef\]](#)