

# Atrial fibrillation following therapy with high-dose i.v. methylprednisolone: A brief case-based review

Ciro Romano, Valentina Sirotti, Vincenza Farinaro, Vittorio Luiso, Eleonora Solaro, Chiara De Sio, Anna Salemme, Andrea Del Mastro, Riccardo Giunta

## Abstract

Atrial fibrillation following high-dose i.v. steroids for treatment of severe immune-mediated diseases has been rarely reported in the literature. Here we report a further case of atrial fibrillation following high-dose i.v. methylprednisolone (HDIVMP) therapy of severe thrombocytopenia in a female patient with a flare-up of systemic lupus erythematosus (SLE). The available literature on this topic is reviewed as well.

**Keywords:** Atrial fibrillation, high-dose steroids, methylprednisolone, systemic lupus erythematosus

## Introduction

High dose i.v. steroids (also known as pulse steroid therapy) are commonly used for severe or life-threatening manifestations of a number of inflammatory or autoimmune diseases. Suprapharmacologic doses of steroids are typically administered i.v. for three to five days to speed recovery and to reduce side effects. Indeed, pulse therapy is deemed to achieve a steroid-sparing effect because the cumulative dose of pulse steroids is less toxic than that of continued steroid treatment at lower doses. In the short term, however, high dose i.v. steroids may be associated with such side effects as a metallic taste in the mouth, nausea, heartburn, sleep problems, mood disturbance, hypertension, weight gain, hyperglycemia, and infections. Rarely, occurrence of arrhythmias has been reported. Here, we report a case of atrial fibrillation following high-dose i.v. methylprednisolone (HDIVMP) therapy of severe thrombocytopenia in a female patient with a flare-up of systemic lupus erythematosus (SLE) and review the available literature on this topic.

## Case Presentation

A 54-year-old female patient was urgently transferred from another hospital to our institution because of severe thrombocytopenia (1000 platelets/ $\mu$ L). She had been previously diagnosed with SLE at age 36. Since then, she was treated with oral steroids only (deflazacort [Deflan; Laboratori Guidotti, Pisa, Italy] 30 mg/day, tapered down to not less than 15 mg/day) since hydroxychloroquine (Plaquenil; Sanofi, Paris, France) caused early retinal accumulation, and no attempts were made to add an immunosuppressant. In the few months preceding the admission to our institution, because of evidence of cataracts in both eyes, cyclosporine (Sandimmun Neoral; Novartis, Basel, Switzerland) was added at a dose of 2.0 mg/kg in order to progressively taper off steroids. However, as deflazacort was tapered down to as low as 15 mg/day, a brisk reduction in blood counts was noted (neutrophils 646 cells/ $\mu$ L; platelets 64000/ $\mu$ L; Hgb 9.8 g/dL). Despite restoring the deflazacort therapy to a higher dosage (45 mg/day), a few days later the patient was admitted to the emergency room of the local hospital because of diffuse skin ecchymoses. Platelets were 1000/ $\mu$ L. The patient was subjected to two platelet transfusions, and the next day was transferred to our hospital. On admission, the patient was alert and oriented. Vital signs were as follows: blood pressure 110/70 mmHg, heart rate 80 bpm and regular, oxygen saturation in ambient air 99%, temperature 36.2°C. Physical examination disclosed only diffuse ecchymoses and a slightly enlarged thyroid. The spleen was within the normal limits. Platelets were 4000/ $\mu$ L on arrival. Thus, therapy with high-dose i.v. steroids was commenced (methylprednisolone [Solu-Medrol; Pfizer, New York, NY, USA] 1 g for three consecutive days, followed by oral prednisone [Deltacortene; Bruno Famaceutici, Rome, Italy] 1 mg/kg; cyclosporin was replaced with azathioprine [Azatioprina Aspen; Aspen Pharma, Dublin, Ireland] 50 mg b.i.d). At the end of the first infusion, the patient complained of sporadic palpitations. Electrocardiogram (ECG) showed sporadic supraventricular premature beats. The patient reported the same complaint the following day. Addition of a beta-blocker was initially considered; however, because of low blood pressure, this therapy was not instituted. At the end of the three days of i.v. methylprednisolone, the patient complained of frequent palpitations. ECG



**Cite this article as:** Romano C, Sirotti V, Farinaro V, Luiso V, Solaro E, De Sio C, et al. Atrial fibrillation following therapy with high-dose i.v. methylprednisolone: A brief case-based review. Eur J Rheumatol 2017; 4: 231-3.

Division of Internal Medicine, Department of Medical and Surgical Sciences, Luigi Vanvitelli University of Campania School of Medicine, Naples, Italy

### Address for Correspondence:

Ciro Romano, Division of Internal Medicine, Department of Medical and Surgical Sciences, Luigi Vanvitelli University of Campania School of Medicine, Naples, Italy

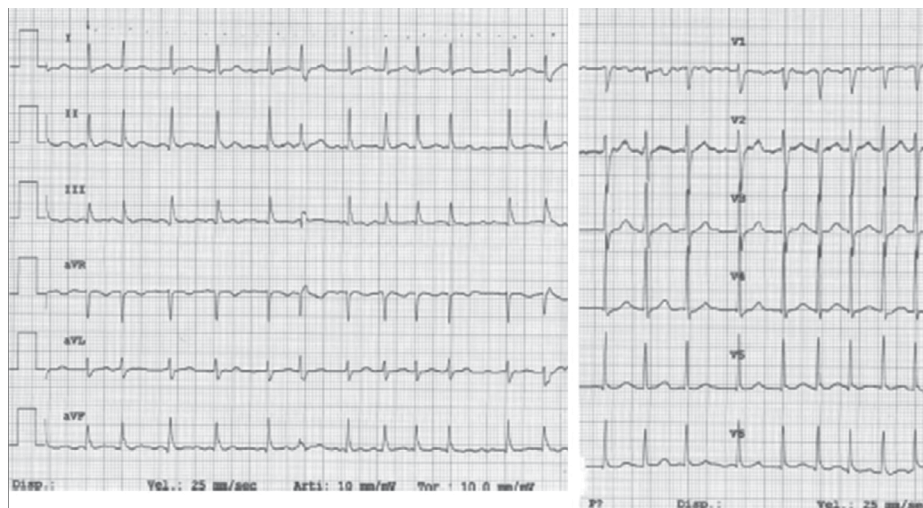
E-mail: ciro.romano@unicampania.it

Submitted: 18 December 2016

Accepted: 14 February 2017

Available Online Date: 21 June 2017

©Copyright by 2017 Medical Research and Education Association - Available online at [www.eurjrheumatol.org](http://www.eurjrheumatol.org).



**Figure 1.** ECG showing atrial fibrillation at an average rate of 120 beats per minute at the end of the third day of high-dose i.v. methylprednisolone therapy  
ECG: electrocardiogram

showed atrial fibrillation (Figure 1). Meanwhile, a further assessment of the platelet count revealed 98000/ $\mu$ L. Because of anecdotal reports of atrial fibrillation possibly related to high-dose steroid administration, the patient was maintained with only 25 mg/day of prednisone. An attempt to pharmacological cardioversion was made, but the patient remained in atrial fibrillation for the following days. Thus, a rate control strategy was adopted, using beta-blockers (Seloken; AstraZeneca, London, UK) in the first place and, because of no rate control, verapamil (Isoptin; Abbott, Chicago, IL, USA) thereafter. Steroids were then temporarily suspended, and high-dose i.v. immunoglobulin (Privigen; CLS Behring, King of Prussia, PA, USA) was infused (2 g/kg/day for two consecutive days). Eventually, the patient reverted to sinus rhythm 4 days later. Thyroid Stimulating Hormone (TSH) and electrolytes were in the normal range, the blood pressure was within normal limits, and antiphospholipid antibodies were not detected. Echocardiography did not disclose abnormalities; particularly, the atria were of normal size, there were no abnormalities in global and segmentary kinetics, and the ventricular septum thickness was within limits. No evidence of coronary artery disease was recorded. Following restoration of sinus rhythm, prednisone was reintroduced at 50 mg/day, with no new episodes of atrial fibrillation. At the latest follow-up (fourteen weeks later), the patient was still in sinus rhythm; platelets and white blood cells were well within the normal limits on prednisone 25 mg/day and azathioprine 100 mg/day. Since the occurrence of atrial fibrillation following high-dose i.v. steroids is a rare adverse event, the patient gave her informed consent for anonymous use of her personal data for scientific purposes.

## Discussion

Hyperkinetic arrhythmias in SLE may be secondary to cardiac involvement, i.e., pericarditis, myocarditis, endocarditis as well as coronary vasculitis. Pericarditis is the most common manifestation of cardiac involvement in SLE; however, new onset atrial fibrillation has rarely been reported in this condition. None of these possibly predisposing conditions were observed in our patient. Indeed, precordial chest pain was never reported nor was a pericardial rub, gallop, or murmur audible on auscultation; lung fields were clear, peripheral edema was not recorded, ischemia was not evident on ECG, and heart dysfunction was not detected on the echocardiography. Conversely, atrial fibrillation following HDIVMP therapy has been anecdotally reported in the literature (1-3). Less frequently, other tachyarrhythmias have also been observed following HDIVMP, such as atrial flutter, supraventricular tachycardia, ventricular tachycardia, etc., pointing to methylprednisolone as a possible inciting agent in likely predisposed individuals (4-6). Intriguingly, atrial fibrillation has been shown to recur in the same patient whenever he was exposed to this therapy, suggesting a causal role for HDIVMP in eliciting cardiac arrhythmias (7). Besides, atrial fibrillation following methylprednisolone therapy has also been reported in different disease settings, such as membranoproliferative glomerulonephritis or multiple sclerosis, suggesting a drug-related effect, rather than a disease-specific predisposing condition (8, 9). Finally, in even rarer instances, high-dose steroid therapy has been associated with fatal arrhythmias.

With regard to timing, several reports have stressed how atrial fibrillation occurred during or soon after completion of a three-day infu-

sion or, at most, within 24-48 h of therapy completion (1). The timing observed in our patient was consistent with previous observations.

Nonetheless, a hypothetical arrhythmogenicity of high-dose methylprednisolone has not been substantiated yet, presumably because of the small number of reported cases. Indeed, as shown by previous studies, serious cardiovascular side effects are not the rule during HDIVMP. It is likely that very high doses (i.e., 1 g/day), rapid infusion rates, and/or underlying cardiac diseases may concur in eliciting cardiac arrhythmias. In this regard, it is interesting to note that methylprednisolone doses of less than 250 mg/day have not been associated with cardiovascular adverse events, although, in likely predisposed individuals, even low oral doses may trigger onset of atrial fibrillation (8, 10). It should also be considered that subclinical myocarditis may be difficult to detect in SLE patients; therefore, a likely predisposing condition may even go undetected.

In the end, how HDIVMP would trigger atrial fibrillation remains mostly speculative; potassium efflux at the cell membrane, development of late potentials, or peripheral vasodilation have been proposed as pathogenic mechanisms. In other cases, anaphylactoid reactions were supposed to induce the arrhythmia. Finally, autonomic influences may have a role in select cases, as pointed out by other investigators.

In conclusion, clinicians familiar with high-dose i.v. steroid therapy should be aware of the possible occurrence of arrhythmic complications. Because no predictive factors have been identified, it would be wise to plan as low as possible doses and longer infusion times, particularly in patients with known or suspected comorbidities.

**Ethics Committee Approval:** Ethics committee approval was received for this study from the ethics committee of the Department of Medical and Surgical Sciences, Luigi Vanvitelli University of Campania School of Medicine, Naples, Italy.

**Informed Consent:** Written informed consent was obtained from the patient who participated in this study.

**Peer-review:** Externally peer-reviewed.

**Author Contributions:** Concept - C.R., V.L., R.G.; Design - C.R., A.D.M.; Supervision - C.R., R.G.; Data Collection and/or Processing - V.S., V.F., E.S., C.D.S.; Analysis and/or Interpretation - C.R., V.L., R.G.; Literature Search - A.S., E.S., C.D.S., A.D.; Writing Manuscript - C.R., V.S.; Critical Review - R.G., A.S.

**Conflict of Interest:** No conflict of interest was declared by the authors.

**Financial Disclosure:** The authors declared that this study has received no financial support.

## References

1. Aslam AK, Vasavada BC, Sacchi TJ, Khan IA. Atrial fibrillation associated with systemic lupus erythematosus and use of methylprednisolone. *Am J Ther* 2001; 8: 303-5. [\[CrossRef\]](#)
2. Yamamura K, Ohga S, Nishiyama K, Doi T, Tsutsumi Y, Ikeda K, et al. Recurrent atrial fibrillation after high-dose methylprednisolone therapy in a girl with lupus-associated hemophagocytic syndrome. *Lupus* 2011; 20: 871-5. [\[CrossRef\]](#)
3. Ueda N, Yoshikawa Y, Chihara M, Kawaguchi S, Niinomi Y, Yasaki T. Atrial fibrillation following methylprednisolone pulse therapy. *Pediatr Nephrol* 1988; 2: 29-31. [\[CrossRef\]](#)
4. Chikanza C, Fernandez L. Arrhythmias after pulse methylprednisolone therapy. *Br J Rheumatol* 1991; 30: 392-3. [\[CrossRef\]](#)
5. Kumari R, Uppal SS. First report of supraventricular tachycardia after intravenous pulse methylprednisolone therapy, with a brief review of the literature. *Rheumatol Int* 2005; 26: 70-3. [\[CrossRef\]](#)
6. Belmonte MA, Cequiere A, Roig-Escofet D. Severe ventricular arrhythmia after methylprednisolone pulse therapy in rheumatoid arthritis. *J Rheumatol* 1986; 13: 477-9.
7. Moretti R, Torre P, Antonello RM, Zorzon M, Cazzato G. Recurrent atrial fibrillation associated with pulse administration of high doses of methylprednisolone: a possible prophylactic treatment. *Eur J Neurol* 2000; 7: 130. [\[CrossRef\]](#)
8. Dogukan A, Ilkay E, Poyrazoglu OK, Gunal AI, Ozgen M, Pekdemir M. Atrial fibrillation due to oral methylprednisolone in a patient with membranoproliferative glomerulonephritis. *Acta Medica (Hradec Králové)* 2008; 51: 63-4. [\[CrossRef\]](#)
9. Vasheghani-Farahani A, Sahraian MA, Darabi L, Aghsaie A, Minagar A. Incidence of various cardiac arrhythmias and conduction disturbances due to high dose intravenous methylprednisolone in patients with multiple sclerosis. *J Neurol Sci* 2011; 309: 75-8. [\[CrossRef\]](#)
10. Erstad BL. Severe cardiovascular adverse effects in association with acute, high-dose corticosteroid administration. *DICP* 1989; 23: 1019-23.