

Etanercept in the treatment of SAPHO syndrome: Which place?

Fatima Ezzahra Abourazzak¹, Hicham Hachimi¹, Nadira Kadi¹, Khadija Berrada¹, Siham Tizniti², Taoufik Harzy¹

Abstract

Synovitis, acne, pustulosis, hyperostosis, and osteitis syndrome (SAPHO) is a rare disease combining skin, bone, and joint manifestations. Its treatment remains a debated issue in the absence of a valid therapeutic strategy. The experience with tumor necrosis factor alpha (TNF alpha)-blocking agents is still small but encouraging. This therapy is reserved for refractory cases. The most commonly used agent is infliximab. Only few cases treated by etanercept have been reported in the literature. We report a new case treated by this biologic therapy and discuss its place in the treatment of SAPHO syndrome. A 30-year-old male, with a history of left clavicular osteitis that required surgical bone biopsy to rule out infection and malignancy, was admitted to the rheumatology department because of recurrent anterior chest pain, lower limb arthralgia, and sacroiliac pain. Laboratory findings revealed an inflammatory syndrome. Conventional radiography and computed tomography (CT) scan of the sternocostoclavicular region showed sclerosis and hyperostosis of the left clavicle. Right sacroiliitis was diagnosed based on the radiographic findings. Moreover, the patient reported palmoplantar pustulosis, thereby strengthening the diagnosis of SAPHO syndrome. As conventional treatment based on methotrexate, corticosteroids, and zoledronic acid was not effective, etanercept was initiated with good and rapid clinical and biological improvement. The diagnosis and treatment of SAPHO syndrome are challenging due to the heterogeneity of symptoms and unknown pathogenesis. Etanercept can be an effective therapy, especially in refractory cases. Further studies are needed in order to establish a therapeutic strategy.

Key words: Anti-TNF alpha, etanercept, SAPHO syndrome

Introduction

Synovitis, acne, pustulosis, hyperostosis, osteitis (SAPHO) syndrome represents a spectrum of various dermatologic and musculoskeletal conditions. The denotation was first proposed in 1987 after investigation of 85 cases. Because precise knowledge of the pathogenesis of SAPHO syndrome is lacking, a variety of therapeutic approaches exists. The therapeutic strategy remains unclear and was largely inspired by that for spondyloarthropathies. Over the years, nonsteroidal anti-inflammatory drugs (NSAIDs), corticosteroids, antibiotics, bisphosphonates, and different types of disease-modifying anti-rheumatic drugs (DMARDs) have been used. The efficacy of bisphosphonates is difficult to assess in the absence of randomized controlled studies and requires more evidence. Nevertheless, in most reports, this treatment is considered effective for chronic active osteitis. The newest treatment is tumor necrosis factor (TNF) alpha-blocking agents. They have been proposed for treatment of refractory SAPHO syndrome with analogy to spondyloarthropathy therapy. We describe a case of SAPHO syndrome treated successfully with etanercept and review cases reported in the literature.

Case Presentation

A 30-year-old man had complained of anterior chest pain with inflammatory arthralgia of the knees, ankles, and feet and sacroiliac pain for 5 years. Pain and arthritis caused disability and limited his walking distance. He had a history of nontraumatic relapsing and remitting left clavicular pain and swelling, for which a bone biopsy was performed by orthopedics to rule out infection and malignancy. Cultures for aerobic and anaerobic bacteria and mycobacterium tuberculosis were negatives, without signs of malignancy. He also reported occasional skin lesions, described as pustular and erythematous, on the palms of his hands and the soles of his feet.

Investigations revealed inflammation with erythrocyte sedimentation rate (ESR) at 87 mm at 1 hour and C-reactive protein (CRP) at 60 mg/L. Right sacroiliitis was diagnosed based on radiographic findings. Ultrasonography showed asymmetric erosive synovitis of ankles. Plain X-ray and computed tomography (CT)



1 Department of Rheumatology,
Hassan II University Hospital, Fez,
Morocco

2 Department of Radiology, Hassan II
University Hospital, Fez, Morocco

Address for Correspondence:
Fatima Ezzahra Abourazzak,
Rheumatology Department, Hassan II
University Hospital, Fez, Morocco

E-mail: f.abourazzak@yahoo.fr

Submitted: 03.06.2014

Accepted: 29.06.2014

Copyright 2014 © Medical Research and
Education Association

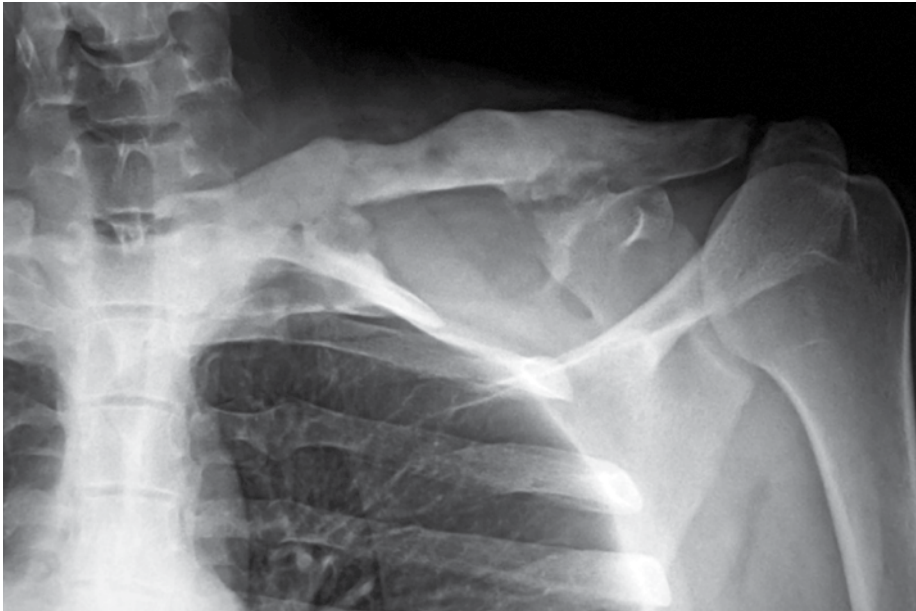


Figure 1. Plain X-ray showing abnormal left clavicle with expansion of this bone and large sclerotic area

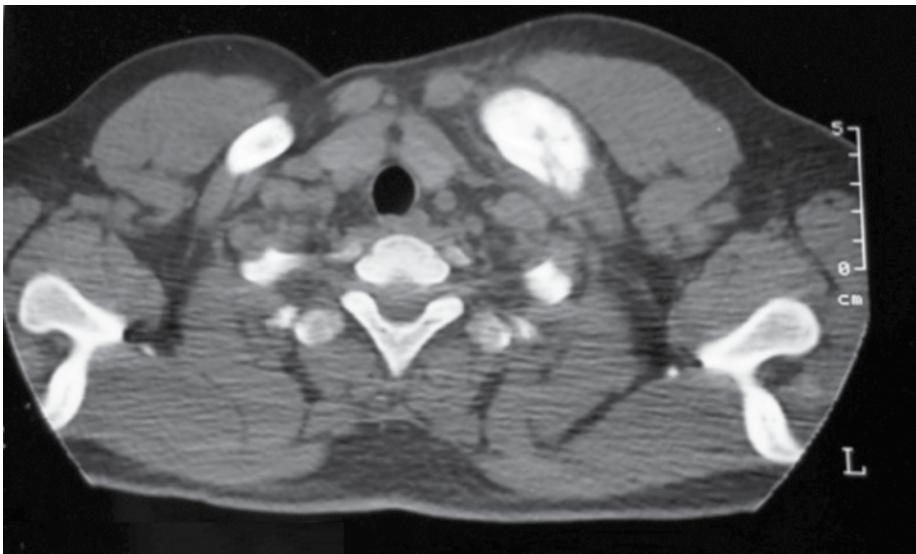


Figure 2. Axial CT scan image of the left clavicle showing sclerosis and increased thickness of cortical bone

scan of the left clavicle showed expansion of this bone with sclerosis and increased thickness of the cortical bone (Figure 1, 2). The diagnosis of SAPHO syndrome was made based on clinical and imaging data.

Methotrexate at a dose of 25 mg/week in association with NSAIDs was started. Sacroiliac pain resolved, but active synovitis of the lower limb joints and clavicular and chest pain persisted, despite the adjunction of prednisone and corticosteroid infiltrations of the ankles. No significant response was noted in the articular or bone lesions 6 months later. The patient continued to suffer progressively more severe, recurrent episodes of arthritis and clavicle pain. We thus administered a one-time an infusion

of 4 mg zoledronic (Zometa; Novartis, East Hanover, NJ) acid. This treatment resulted in a 20% decrease in pain, which was evaluated 3 weeks after infusion, with rapid recrudescence of osteoarticular symptoms.

Because conventional treatment was unsuccessful, anti-TNF alpha therapy was initiated based on etanercept 25 mg (Enbrel; Wyeth Pharmaceuticals, New Lane, Havant, Hampshire, PO9 2NG, UK) twice a week in association with methotrexate, with good improvement after the first month. We noted a rapid reduction in pain and swelling. He got back to normal activity. The inflammatory parameters decreased: ESR at 7 mm at 1 hour and CRP at 16 mg/L. Currently, 1 year after starting etaner-

cept, the patient is symptom-free, with an occasional short episode of clavicle and articular pain. No adverse effect was noted, with good tolerance of treatment.

Discussion

Because of the unknown pathogenesis of SAPHO syndrome, its low incidence, and different patterns of disease expression, there is no well-established therapy. Therapeutic options for SAPHO syndrome are currently limited and often based on isolated cases and reports of small series of patients. Treatment is mostly empirical and based on the use of corticosteroids, NSAIDs, DMARDs, antibacterials (azithromycin, doxycycline, sulfamethoxazole/trimethoprim), bisphosphonates, TNF alpha antagonists, and recently anti-interleukin (IL) 1 (1).

Anti-TNF alpha therapy is proposed in refractory SAPHO syndrome, based on its efficacy in spondyloarthropathies. Additional evidence of favorable clinical outcomes with anti-TNF alpha therapy for SAPHO syndrome patients was given by medical observations. Indeed, intense expression and production of TNF alpha have been observed in bone biopsy specimens of two patients by *in situ* hybridization and immunohistochemistry (1). Also, in a series of 29 patients, SAPHO syndrome demonstrated elevated IL-8 and IL-18 plasma levels. IL-8 and TNF alpha production by purified neutrophils was higher than in healthy controls, with normal levels of oxidative burst and IL-18 production. But, the induction of neutrophil IL-8 and TNF alpha production by *P. acnes* was impaired in the SAPHO group. Interestingly, neutrophil IL-8 and TNF- α production decreased after 28 days of etanercept treatment. The study failed to detect autoantibodies in SAPHO patients (1).

The rationale of the use of anakinra, a recombinant human IL-1 receptor antagonist, in SAPHO syndrome is based on recent observations. Colina and colleagues measured IL-1b secretion in the presence of stimulators or blockers of the P2X7 receptor, a major activator of the inflammasome complex and, therefore, of IL-1b processing and release and found that the level of expression of the P2X7 receptor was about 1.75-fold higher in SAPHO than in healthy control leukocytes, suggesting possible dysregulation of the IL-1b processing machinery (2).

The use of anti-TNF- α therapies in refractory SAPHO syndrome is increasing. In the literature, infliximab was the most common anti-TNF alpha used, with more than 20 reported cases since 2002 (1). Response was mainly excellent and rapid after the first infusions and sustained

Table 1. SAPHO syndrome treated with etanercept in the literature

Author	Sex/ Age	Osteoarticular findings	Skin involvement	Duration	Prior treatment	Anti-TNF therapy	Delay response	Outcome	Side effect	Follow-up
Wagner	F/44	Hyperostosis of mandible	PPP	3 years	NSAIDs, CTX, ATB, MTX, BP	ETN	1 week	Improvement of symptoms	-	9 months
	F/41	Sternal hyperostosis	No	8 years	CTX, MTX, CSA, BP	INF (stopped, after bronchospasm) then ETN	-	Improvement of symptoms	-	9 months
Ben Abdelghani	F/36	Chest wall osteitis	PPP	7 years	NSAIDs, CTX, MTX	INF (Paradoxical psoriasis) then ETN	-	No response after 3 months	-	3 months
	F/53	Chest wall osteitis	-	13 years	NSAIDs, MTX, BP	ETN	-	Resolution of symptoms	-	1 month
	F/29	Chest wall osteitis	PPP	4 years	NSAIDs, BP	INF (Paradoxical psoriasis) then ETN	1 week	Remission of bone pain and skin lesions	-	42 months
Coloe	M/15	Chest pain Osteitis, Arthritis Back pain	Severe acne	several months	ATB, Isotretinoin, CTX, NSAIDs, MTX,	ETN	-	Improvement of musculoskeletal symptoms	-	-
Vilar-Alejo	M/47	Arthritis Axial manifestations	Acne conglobata Hidradenitis suppurativa Perifolliculitis abscedens	8 years	ATB, Isotretinoin, NSAIDs, SLZ, BP, CSA	ETN	4 weeks	Improvement of cutaneous and arthritic symptoms	Cutaneous infection after 3 months	32 months
Wolber	Child	Sacroiliitis	Acne conglobata	-	CTX	ETN	Few days	Improvement of pain and disability	-	8 months
Zhang	F/56	Chest pain, Spine inflammation	PPP	6 years	NSAIDs, BP, SLZ,	ETN	1 week	Improvement of pain but recurrence of PPP	-	3 months
Su Ahead of print	M/42	Chest pain Arthritis	Acne conglobata	5 years	ATB, NSAIDs, CTX, SLZ, MTX, Isotretinoin,	ETN	-	Improvement of musculoskeletal and cutaneous lesions after 6 weeks	-	6 months

PPP: palmoplantar pustulosis; CTX: corticosteroids; NSAIDs: non-steroidal anti-inflammatory drugs; ATB: antibiotics; SLZ: salazopyrin; MTX: methotrexate; BP: bisphosphonates; CSA: cyclosporine; ETN: etanercept; INF: infliximab

after several months, and discontinuation resulted in relapse or adverse effects; however, the response was not as good in patients with palmoplantar pustulosis (PPP) (3). Adalimumab was used in five cases and yielded an excellent response in cutaneous (3 PPP and 1 severe acne conglobata) as well as articular symptoms, with follow-up ranging from 1 to 24 months (4). Etanercept was the alternative therapy in refractory SAPHO syndrome in 10 reported cases (1, 5-8). Characteristics of these observations are given in Table 1.

Etanercept was used as the first biologic therapy in the majority of cases, and it showed a rapid positive response, except in one case, with good tolerance and sustained response. Our case suggests that the efficacy of etaner-

cept therapy is in accordance with the cases described in the literature.

Several studies indicate that bisphosphonates may have anti-inflammatory activity, reducing the secretion of pro-inflammatory cytokines (IL-1, IL-6, and TNF alpha) and inhibiting macrophage functions. Furthermore, bisphosphonates have anti-osteoclastic activity that limits bone resorption. Thus, their use may be effective in the treatment of osteitis of SAPHO syndrome.

Intravenous bisphosphonates, mainly pamidronate, were reported to be effective in some cases. Their use can produce partial or complete remission in a significant number of patients (9, 10). An open-label study found pamidronate to be markedly beneficial in 56% of cases and

to elicit a partial response in 33% of cases (9). A study analyzing 14 patients with SAPHO syndrome who had a predominantly relapsing-remitting course and were prescribed intravenous pamidronate 60 mg daily for 3 consecutive days showed a good response in 12 patients and sustained remission in 8 patients (10). The use of other intravenous bisphosphonate has been reported. Zoledronate was, in contrast to our case, a successful treatment in two cases, and ibandronate was successful in one case.

As a conclusion, we encourage administration of anti-TNF alpha therapy, especially etanercept, in patients with SAPHO syndrome who do not respond to conventional treatment, including at least one DMARD. Further studies and reported cases are needed to support our observation.

Informed Consent: Written informed consent was obtained from patient who participated in this study.

Peer-review: Externally peer-reviewed.

Author contributions: Concept - F.A., H.H., T.H.; Design - F.A., H.H., N.K., K.B.; Supervision - F.A., T.H.; Resource - F.A., H.H., S.T.; Materials - F.A., H.H., N.K., K.B.; Data Collection&/or Processing - F.A., H.H., N.K., K.B.; Analysis&/or Interpretation - F.A., H.H., S.T., T.H.; Literature Search - F.A., H.H., N.K., K.B., S.T.; Writing - F.A., H.H., ; Critical Reviews - T.H., S.T.

Conflict of Interest: No conflict of interest was declared by the authors.

Financial Disclosure: The authors declared that this study has received no financial support.

References

- Hayem G, Bouchaud-Chabot A, Benali K, Roux S, Palazzo E, Silbermann-Hoffman O, et al. SAPHO syndrome: a long-term follow-up study of 120 cases. *Semin Arthritis Rheum* 1999 ; 29: 159-71. [\[CrossRef\]](#)
- Colina M, Pizzirani C, Khodeir M, Falzoni S, Bruschi M, Trotta F, et al. Dysregulation of P2X7 receptor-inflammasome axis in SAPHO syndrome: successful treatment with anakinra. *Rheumatology (Oxford)* 2010; 49: 1416-8. [\[CrossRef\]](#)
- Massara A, Cavazzini PL, Trotta F. In SAPHO syndrome anti-TNF-alpha therapy may induce persistent amelioration of osteoarticular complaints, but may exacerbate cutaneous manifestations. *Rheumatology (Oxford)* 2006; 45: 730-3. [\[CrossRef\]](#)
- Castellví I, Bonet M, Narváez JA, Molina-Hinojosa JC. Successful treatment of SAPHO syndrome with adalimumab: a case report. *Clin Rheumatol* 2010; 29: 1205-7. [\[CrossRef\]](#)
- Vilar-Alejo J, Dehesa L, de la Rosa-del Rey P, Novoa-Medina J, ValerónAlmazán P, Santana Medina N. SAPHO syndrome with unusual cutaneous manifestations treated successfully with etanercept. *Acta Derm Venereol* 2010; 90: 531-2. [\[CrossRef\]](#)
- Wolber C, David-Jelinek K, Udvardi A, Artacker G, Volc-Platzer B, Kurz H. Successful therapy of sacroiliitis in SAPHO syndrome by etanercept. *Wien Med Wochenschr* 2011; 161: 204-8. [\[CrossRef\]](#)
- Zhang LL, Zhao JX, Liu XY. Successful treatment of SAPHO syndrome with severe spinal disorder using entercept: a case study. *Rheumatol Int* 2012; 32: 1963-5. [\[CrossRef\]](#)
- Su YS, Chang CH. SAPHO syndrome associated with acne conglobata successfully treated with etanercept. *J Formos Med Assoc* 2013; ahead of print.
- Amital H, Applbaum YH, Amar S, Daniel N, Rubinow A. SAPHO syndrome treated with pamidronate: an open-label study of 10 patients. *Rheumatology (Oxford)* 2004; 43: 658-61. [\[CrossRef\]](#)
- Colina M, La Corte R, Trotta F. Sustained remission of SAPHO syndrome with pamidronate: a follow-up of fourteen cases and a review of the literature. *Clin Exp Rheumatol* 2009; 27: 112-5.