

Breast calcinosis in a patient with Dermatomyositis

Rajaie Namas^{1,3}, Nassar Beydoun², Alireza Meysami³

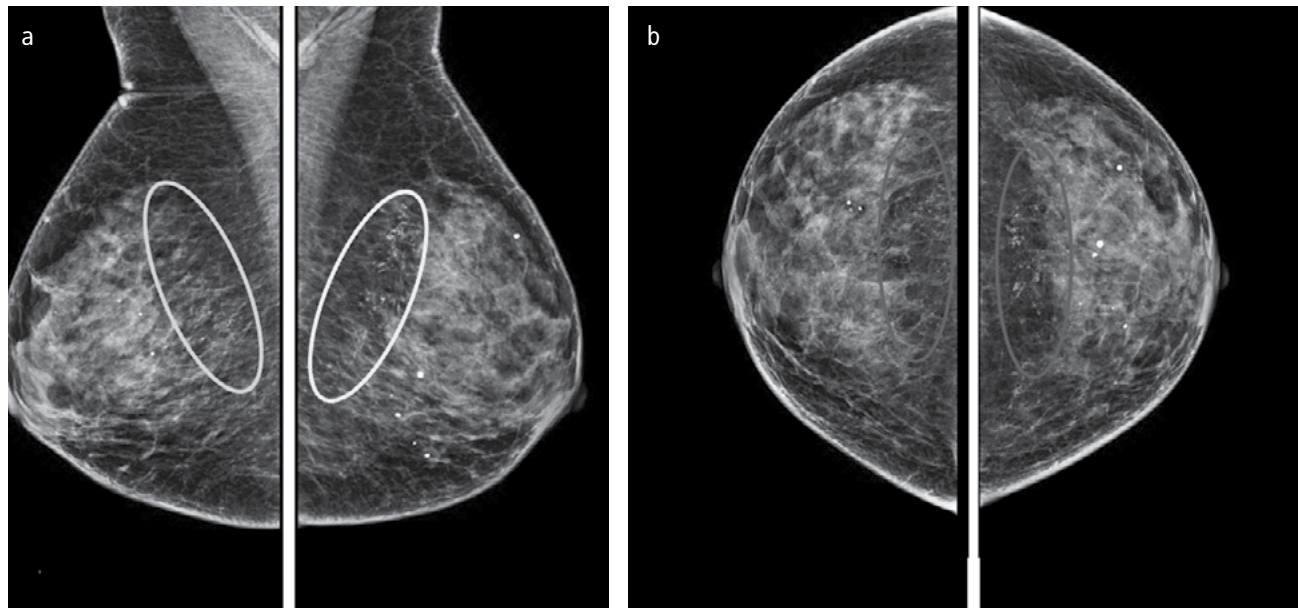


Figure 1. a, b. Mediolateral oblique view (a) and craniocaudal view (b) of the mammography showing unusual, sheet-like dystrophic calcifications in the subcutaneous tissues, which are regionally distributed at the top and toward the center at a posterior depth. The left side was affected to a greater extent than the right.

1 Department of Internal Medicine, Division of Rheumatology, University of Michigan, Ann Arbor, Michigan, United States of America

2 Department of Radiology, Division of diagnostic radiology, Henry Ford Hospital, Detroit, Michigan, United States of America

3 Department of Internal Medicine, Division of Rheumatology, Henry Ford Hospital, Detroit, Michigan, United States of America

Address for Correspondence:
Rajaie Namas, Department of Internal Medicine, Division of Rheumatology, University of Michigan, Ann Arbor, MI, USA

E-mail: rnamas@med.umich.edu

Submitted: 11.10.2015

Accepted: 20.12.2015

Available Online Date: 05.04.2016

Copyright 2016 © Medical Research and Education Association

A 71-year-old woman presented with a pruritic macular rash on her chest that progressed to involve the limbs, face, and scalp. In addition, the rash was associated with progressive proximal muscle weakness that was symmetrically distributed, dysphagia, and fatigue over the past 6 months. A skin examination revealed Gottron's and shawl signs. She underwent a skin biopsy that revealed perivascular lymphocytic infiltration and interface dermatitis. This was consistent with the diagnostic findings of dermatomyositis (DM). Moreover, electromyography was consistent with a myopathic pattern, and the muscle biopsy revealed a well-defined perifascicular distribution of muscle fiber injury with sparse collections of inflammatory cells predominantly surrounding the perimysial vessels and muscle fibers. These characteristics were diagnostic of DM (1).

Routine and serological tests revealed that both erythrocyte sedimentation rate and C-reactive protein levels were elevated. The patient was reluctant to undergo prednisone or intravenous immunoglobulin therapy, and she was administered methotrexate instead. She exhibited a good response to treatment. Age- and risk-appropriate screening was performed, which was negative for malignancy. Interestingly, a mammogram revealed bilateral, unusual, coarse, heterogeneous, branched, and sheet-like calcifications, which were regionally distributed at the top and spanned toward the center at a posterior depth. In addition, the left side was affected to a greater extent than the right, which is compatible with benign subcutaneous calcifications associated with DM (Figure 1a, b).

Diffuse dystrophic calcifications of the subcutaneous fat that become progressively coarser over time may be seen in collagen vascular diseases such as scleroderma, DM, and systemic lupus erythematosus. Patients with DM may develop unusual, sheet-like dystrophic calcifications in the subcutaneous tissue that could be

either localized or extensive (2, 3), as observed in the mammogram of our patient.

Dermatomyositis is a heterogeneous disease of the connective tissue characterized by an inflammatory process involving the skin, skeletal muscles, and various connective tissues (4). Soft tissue calcifications termed “calcinosis” are common in approximately 10%–40% of patients with juvenile DM but are unusual in patients with adult-onset DM (5). Risk factors attributed to the development of calcinosis include young age and delayed diagnosis or therapy. Interestingly, the incidence of calcinosis was inversely proportional to creatinine phosphokinase levels (6). In summary, given the associated risk between DM and malignancy, physicians should be aware that this finding

can occur within 4 months or up to 12 years from the onset of disease.

Ethics Committee Approval: N/A.

Informed Consent: Written informed consent was obtained from the patient.

Peer-review: Externally peer-reviewed.

Author Contributions: Concept - R.N., N.B., A.M.; Design - R.N., A.M.; Supervision - R.N., A.M.; Materials - R.N., A.M.; Data Collection and/or Processing - R.N., A.M.; Analysis and/or Interpretation - R.N., N.B., A.M.; Literature Review - R.N., A.M.; Writer - R.N., A.M.; Critical Review - R.N., A.M.

Conflict of Interest: No conflict of interest was declared by the authors.

Financial Disclosure: Rajaie Namas is supported by the National Institute of Arthritis and Musculoskeletal and Skin Diseases, grant number T32AR007080-37.

References

1. Khan S, Christopher-Stine L. Polymyositis, dermatomyositis, and autoimmune necrotizing myopathy: clinical features. *Rheum Dis Clin North Am* 2011; 37: 143-58. [\[CrossRef\]](#)
2. Feder JM, Shaw de Paredes E, Hogge JP, Wilken JJ. Unusual breast lesions: radiologic-pathologic correlation. *Radiographics* 1999; 19: 11-26. [\[CrossRef\]](#)
3. Gyves-Ray KM, Adler DD. Dermatomyositis. An unusual cause of breast calcification. *Breast Disease* 1989; 2: 195-201.
4. Dalakas MC. Inflammatory Muscle Diseases. *N Engl J Med* 2015; 373: 393-4. [\[CrossRef\]](#)
5. Callen JP. Dermatomyositis. *Lancet* 2000; 355: 53-7. [\[CrossRef\]](#)
6. Weinel S, Callen J. Calcinosis cutis complicating adult-onset dermatomyositis. *Arch Dermatol* 2004; 140: 365-6. [\[CrossRef\]](#)