

Hemophagocytic lymphohistiocytosis after certolizumab treatment in a patient with rheumatoid arthritis

Göksel Güven¹, Aslıhan Güler², Nil Özyüncü³, Leyla Talan¹, Aylin Heper⁴, Tahsin Murat Turgay⁵, Neriman Defne Altıntaş¹

Abstract

Hemophagocytic lymphohistiocytosis (HLH) is a rare and life-threatening syndrome that may be triggered by hereditary factors, autoimmune and immunologic disorders, infectious diseases, malignancies and medications. Suspicion of the disease and early treatment is of paramount importance. Since the presentation of HLH with only skin involvement is rare, early diagnosis may be difficult. A pathologically confirmed HLH case that presented with maculopapular skin lesions after certolizumab treatment is being reported in this presentation.

Keywords: Hemophagocytic lymphohistiocytosis, rheumatoid arthritis, certolizumab, skin involvement



ORCID IDs of the authors:

G.G. 0000-0002-6916-8907,
A.G. 0000-0001-9866-9797,
N.Ö. 0000-0002-1845-5287,
L.T. 0000-0003-2023-5985,
A.H. 0000-0003-3954-2889,
M.T. 0000-0001-5302-4485,
D.A. 0000-0002-7885-8942

Cite this article as: Güven G, Güler A, Özyüncü N, Talan L, Heper A, Turgay TM, et al. Hemophagocytic lymphohistiocytosis after certolizumab treatment in a patient with rheumatoid arthritis. *Eur J Rheumatol* 2018; 10.5152/eurjrheum.2018.17108

¹Department of Internal Medicine, Division of Intensive Care, Ankara University School of Medicine, Ankara, Turkey

²Department of Internal Medicine, Ankara University School of Medicine, Ankara, Turkey

³Department of Cardiology, Ankara University School of Medicine, Ankara, Turkey

⁴Department of Pathology, Ankara University School of Medicine, Ankara, Turkey

⁵Department of Rheumatology, Ankara University School of Medicine, Ankara, Turkey

Address for Correspondence:

Göksel Güven, Department of Internal Medicine, Division of Intensive Care, Ankara University School of Medicine, Ankara, Turkey.

E-mail: drgoksel@hotmail.com

Submitted: 10 September 2017

Accepted: 21 October 2017

Available Online Date: 13 February 2018

©Copyright by 2018 Medical Research and Education Association - Available online at www.eurjrheumatol.org.

Introduction

Hemophagocytic lymphohistiocytosis (HLH) is a rare, rapidly progressive, and fatal disorder if untreated. Hemophagocytosis is the engulfment of hematopoietic cells by activated macrophages in tissue specimens. HLH covers a variety of related diseases, including familial HLH, familial erythrophagocytic lymphohistiocytosis, viral-associated hemophagocytic syndrome, and autoimmune associated macrophage activation syndrome. Familial HLH is an autosomal recessive disease and is diagnosed within the first 2 years of life; adult-onset primary HLH is rare (1). The etiology of secondary HLH includes viral infections (29%), other infections (20%; bacterial, protozoal, and fungal), malignancies (27%), rheumatologic disorders (7%), and immune deficiency syndromes (6%) (2). Because of the high mortality rate, suspecting the disease, early treatment, and aggressive supportive care are critical for patients with HLH. In this report, a fatal HLH case that developed after certolizumab treatment has been presented.

Case Presentation

A 49-year-old woman was admitted to the intensive care unit (ICU) because of progressive multiple organ dysfunctions. Her medical history included rheumatoid arthritis (RA), hypertension, Addison's disease, and hyperlipidemia. Her medications included ramipril for hypertension and methylprednisolone and fludrocortisone for Addison's disease. She was diagnosed with RA 2 months prior to admission to the ICU. Plaquenil 400 mg/day and certolizumab pegol were initiated 2 and 6 weeks following diagnosis, respectively. On the fourth day following certolizumab injection at the rheumatology clinic, she presented with a new onset of maculopapular, desquamating cutaneous lesions on the forearms and hands; in addition, small necrotic areas were present (Figures 1a/1b/1c). She refused hospitalization. On day 7, she was admitted because of deterioration in her condition. The following day she was admitted to the ICU after a tonic-clonic seizure. Arterial blood gas analysis revealed high anion gap metabolic acidosis. Elevated liver enzymes (alanine aminotransferase/aspartate aminotransferase, 318/456 U/L), creatinine levels (7.4, mg/dL), and creatinine kinase levels (3523 U/L) prompted an investigation for possible causes of multiorgan dysfunction. A broad-spectrum antibiotic therapy after microbiological sampling was initiated until sepsis could be ruled out.

The decrease in hemoglobin levels without overt bleeding prompted a search for hemolysis. The blood smear showed acanthosis and schistocytes; thrombotic thrombocytopenic purpura (TTP) could not be ruled out because she had hemolytic anemia (hemoglobin, 8.8 g/dL), thrombocytopenia ($88 \times 10^9/L$), acute renal failure, seizures, and new onset fever (39°C). In addition to these findings, hemophagocytic syndrome could not be ruled out because the ferritin level was 1019 U/L (Normal range (NR):11-307 U/L), fibrinogen was 1.44 g/L (NR: 2-3.93 U/L), triglyceride was 165 mg/dL, and lactate dehydrogenase was 2165 U/L (NR: 125-220 U/L). Direct coombs test was positive and indirect coombs test was negative. Plasma exchange

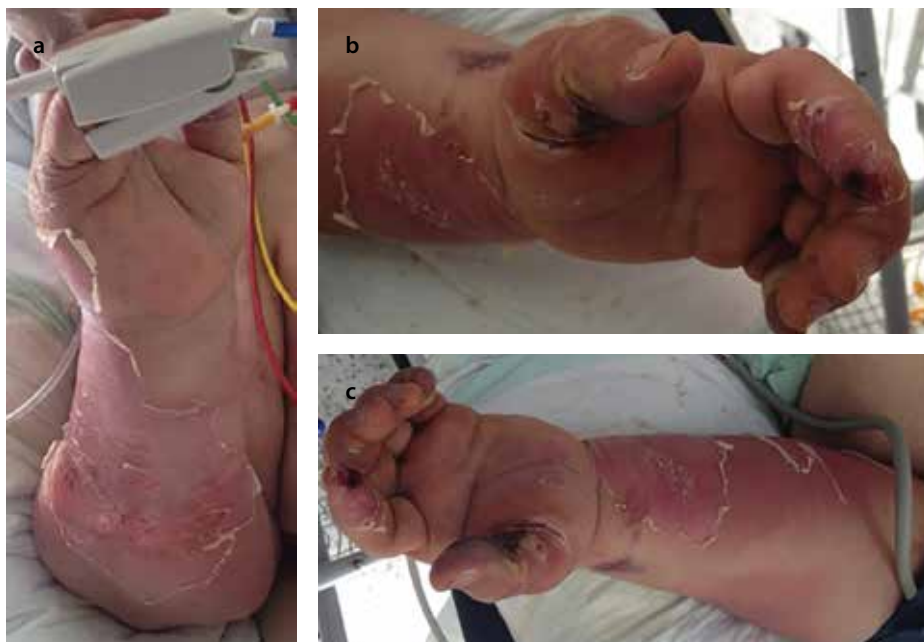

Figure 1. a-c. The palmar region of the left hand showed necrotic lesions and eroded areas with hemorrhagic crusts especially prominent on the finger tips and first finger extending to the dorsum of the finger and causing a circumscribed eroded area. The flexor forearm showed desquamation on both sides with adjacent apparent erythema and induration on the left side

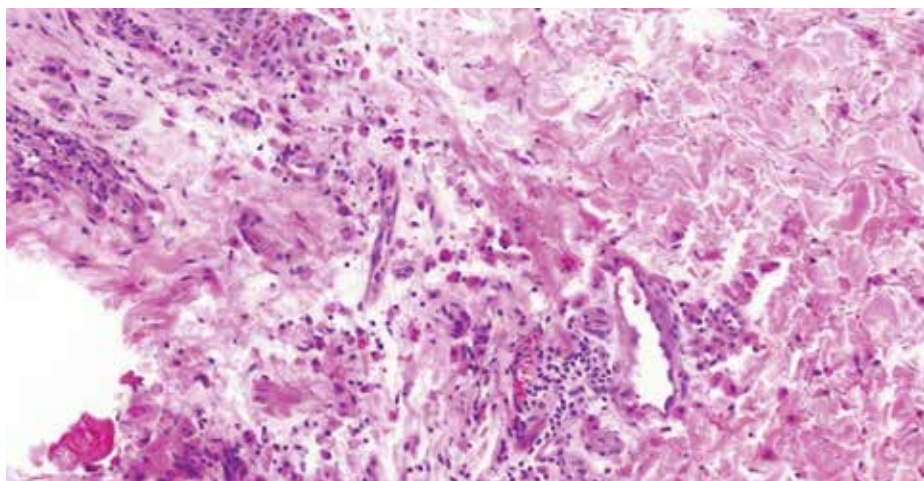


Figure 2. Mild lymphohistiocytic infiltration at the dermis. Lymphocytes are mainly located around the perivascular area. Histiocytes are more scattered; H&E X19

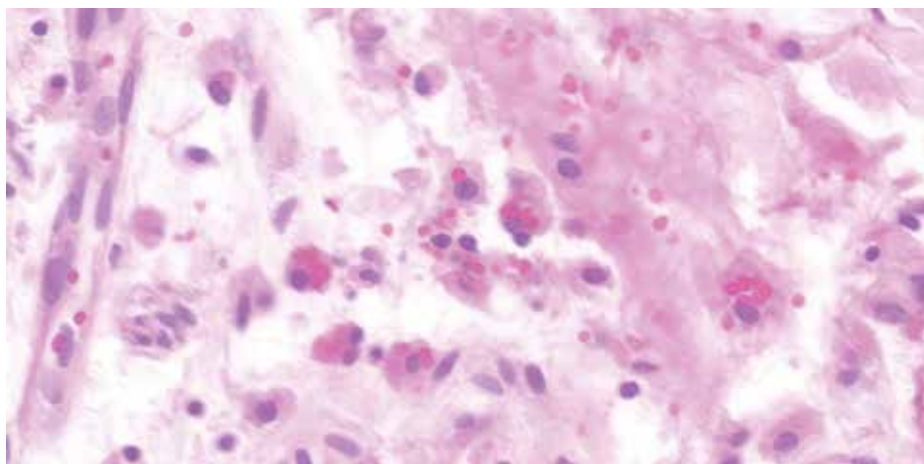


Figure 3. This figure shows numerous histiocytes with phagocytosed erythrocytes inside their cytoplasm. Extravasated erythrocytes can also be observed at the background; H&E X 68

treatment was initiated. Methylprednisolone was administered at a dose of 75 mg/day. Intermittent hemodialysis was initiated.

Necrotic areas on the fingers led to the suspicion of septic embolization, but a formation of vegetation or any other pathology were not detected on echocardiography.

A skin biopsy was performed on one of the active lesions present on her forearm and hand, with the tentative diagnosis of Sweet and hemophagocytic syndromes at the third day of admission to ICU. Bone marrow biopsy was planned for the day after. However, on the next day, her health status deteriorated, respiratory failure and cardiac arrhythmia occurred, and the patient died on the fourth day in the ICU. Skin biopsy showed mild epidermal acanthosis with mild dermal lymphohistiocytic infiltration (Figure 2). There was also massive erythrocyte extravasation at the deep dermis. Some of the histiocytes demonstrated phagocytosed erythrocytes inside the cytoplasm (Figure 3). Pathology report of her skin biopsy was in accordance with HLH.

The patient was diagnosed with HLH. Fever (39°C), bicytopenia (hemoglobin, 8.8 g/dL) thrombocytopenia ($88 \times 10^9/L$), hypofibrinogenemia (1.44 g/L), and high ferritin (1019 ng/ml) were compatible with the criteria used in the HLH-2004 trial (3). Bone marrow, spleen, lymph nodes, or liver biopsies were not performed; however, dermal lymphohistiocytic infiltration with phagocytosed erythrocytes were seen in skin biopsy specimens. There was no splenomegaly which is incompatible with HLH-2004 criteria. Soluble interleukin (IL)-2 level and natural killer-cell activity could not be measured due to lack of availability of these tests.

The cytomegalovirus (CMV) load was reported to be 3481 copy/mL, but there was no sign of CMV infection in the biopsy material. Blood, urine, and endotracheal aspirate cultures were reported to be negative for infection. ADAMTS 13 level was reported to be incompatible with TTP. Toxic epidermal necrolysis (TEN) and Stevens-Johnson Syndrome (SJS) were unlikely due to the lack of histopathological findings and mucosal involvement, and the skin lesions were limited to the hands of the patient.

We routinely solicit patients' consent on admission to utilize their medical records for medical research on the condition that they will be de-identified. The patient's relatives provided the consent.

Discussion

Tumor necrosis factor (TNF)- α antagonists, an effective treatment choice for a variety of autoimmune and inflammatory diseases, have been increasingly recognized as an important part of therapeutic regimens. However, besides their beneficial effects, TNF- α antagonists may trigger the onset of new autoimmune diseases and conditions in some cases. Certolizumab pegol (Cimzia), a new TNF- α antagonist, is the antigen-binding fragment (Fab) of a humanized monoclonal anti-TNF antibody linked to polyethylene. Certolizumab is approved by FDA in 2008 and has been used for patients with RA, Crohn's disease, ankylosing spondylitis, and psoriatic arthritis. The reported autoimmune and inflammatory conditions related to certolizumab include uveitis, nephrotic syndrome, oral lichen planus, interstitial lung disease, erythema nodosum, and fatal fibrosing alveolitis (4, 5).

In our knowledge, there are only a few HLH cases reported after use of anti-TNF- α agents. HLH has been reported in two RA patients on treatment with infliximab, secondary to *Escherichia coli* sepsis (6). In three patients (two of them with JRA and one with adult-onset Still disease) on etanercept treatment, HLH was reported: one had concomitant Epstein-Barr virus (EBV) infection and in another patient, HLH followed an urticarial eruption at the etanercept injection site (7). According to these reports, HLH was thought to be a result of immunosuppressive effects of anti-TNF- α agents. Likewise in a study reported by Araki, a patient with RA developed lupus-like syndrome and HLH after etanercept treatment (8).

Although adverse dermatological reactions, such as skin rash, alopecia, dermatitis, erythema nodosum, and urticaria have been reported with certolizumab, to the best of our knowledge, this is the first reported case of HLH with cutaneous involvement that developed after certolizumab injection. Cutaneous findings are seen in 6% to 65% of the patients with HLH. Most patients with HLH and cutaneous findings present with nonspecific maculopapular eruption, purpura, erythroderma, and edema (9). Only five cases of isolated cutaneous hemophagocytosis, without systemic signs, have been reported, and one of them had de-

veloped after alemtuzumab therapy (10). HLH secondary to hydroxychloroquine, which is also one of the medications used in the presented case, is uncommon. Adverse dermatologic reactions mostly manifest as skin hyperpigmentation; however, TEN/SJS was reported after hydroxychloroquine use as well (11). Skin findings and time intervals between injection and clinical deterioration made certolizumab more liable for this case.

Despite improvement in the treatment of HLH, the mortality rate is still high. Salvage therapies are being used for HLH refractory to standard protocols. Antibodies, such as alemtuzumab (targets CD-52 antigen), infliximab (targets TNF), and daclizumab (targets CD-25), have been successfully used in various refractory cases (1). In addition, etanercept has proved to be effective in a case with acute HLH secondary to lupus. Two patients with systemic lupus erythematosus and two with RA, which were considered as autoimmune diseases related to HLH, have been treated successfully with etanercept and infliximab therapies (12).

To conclude, to the best of our knowledge, this is the first case of HLH in an RA patient, which developed after certolizumab treatment. Concomitant CMV infection may be an aggravating factor. However, it is notable that although anti-TNF- α agents can be the choice of treatment for HLH, they can also be the cause or trigger factor of HLH. Considering the widespread use of anti-TNF- α agents, clinicians should be aware of possible complications.

Informed Consent: Written informed consent was obtained from all the patients who participated in this study.

Peer-review: Externally peer-reviewed.

Author Contributions: Concept - G.G., N.D.A., N.O., M.T., A.H., L.T., A.G.; Design - G.G., N.D.A., N.O., M.T., A.H., L.T., A.G.; Supervision - G.G., N.D.A., N.O., M.T., A.H., L.T., A.G.; Data Collection and/or Processing - G.G., N.D.A., M.T., A.H., L.T., A.G.; Analysis and/or Interpretation - G.G., N.D.A., M.T., L.T., A.G.; Literature Search - G.G., N.D.A., M.T., A.H.; Writing Manuscript - G.G., N.D.A., N.O., M.T., A.H., L.T., A.G.; Critical Review - G.G., N.D.A., L.T., N.O., A.G.

Conflict of Interest: No conflict of interest was declared by the authors.

Financial Disclosure: The authors declared that this study has received no financial support.

References

- George MR. Hemophagocytic lymphohistiocytosis: review of etiologies and management. *J Blood Med* 2014; 5: 69-86. [\[CrossRef\]](#)
- Dhote R, Simon J, Papo T, Detournay B, Sailler L, Andre MH, et al. Reactive hemophagocytic syndrome in adult systemic disease: report of twenty-six cases and literature review. *Arthritis and rheumatism* 2003; 49: 633-9. [\[CrossRef\]](#)
- Henter JI, Horne A, Arico M, Egeler RM, Filipovich AH, Imashuku S, et al. HLH-2004: Diagnostic and therapeutic guidelines for hemophagocytic lymphohistiocytosis. *Pediatr Blood Cancer* 2007; 48: 124-31. [\[CrossRef\]](#)
- Gaspolo I, Hoy R, Ryan P. Comment on: A case of certolizumab-induced interstitial lung disease in a patient with rheumatoid arthritis: reply. *Rheumatology (Oxford)* 2014; 53: 1155. [\[CrossRef\]](#)
- Biedermann L, Kerl K, Rogler G, Hofbauer GF. Drug-induced erythema nodosum after the administration of certolizumab in Crohn's disease. *Inflamm Bowel Dis* 2013; 19: E4-6. [\[CrossRef\]](#)
- Oda Y, Urushidani Y, Ooi S, Endoh A, Nakamura R, Adachi K, et al. Hemophagocytic lymphohistiocytosis in a rheumatoid arthritis patient treated with infliximab. *Intern Med* 2012; 51: 655-7. [\[CrossRef\]](#)
- Sawar H, Espinoza LR, Gedalia A. Macrophage activation syndrome and etanercept in children with systemic juvenile rheumatoid arthritis. *J Rheumatol* 2004; 31: 623.
- Araki D, Fujii H, Matsumura M, Yamagishi M, Yachie A, Kawano M. Etanercept-induced lupus accompanied by hemophagocytic syndrome. *Intern Med* 2011; 50: 1843-8. [\[CrossRef\]](#)
- Fardet L, Galicier L, Vignon-Pennamen MD, Regnier S, Noguera ME, de Labarthe A, et al. Frequency, clinical features and prognosis of cutaneous manifestations in adult patients with reactive haemophagocytic syndrome. *Br J Dermatol* 2010; 162: 547-53. [\[CrossRef\]](#)
- Jawed SI, Busam K, Wang X, Horwitz S, Querfeld C. Cutaneous hemophagocytosis after alemtuzumab injection in a patient with Sezary syndrome. *JAMA Dermatol* 2014; 150: 1021-3. [\[CrossRef\]](#)
- Lateef A, Tan KB, Lau TC. Acute generalized exanthematous pustulosis and toxic epidermal necrolysis induced by hydroxychloroquine. *Clin Rheumatol* 2009; 28: 1449-52. [\[CrossRef\]](#)
- Ideguchi H, Ohno S, Takase K, Hattori H, Kirino Y, Takeno M, et al. Successful treatment of refractory lupus-associated haemophagocytic lymphohistiocytosis with infliximab. *Rheumatology (Oxford)* 2007; 46: 1621-2. [\[CrossRef\]](#)