

# Aortic aneurysm and dissection in systemic lupus erythematosus-pathophysiologic and therapeutic considerations

Nicholas G. Kounis<sup>1</sup> , Ioanna Koniari<sup>2</sup> , Dimitrios Velissaris<sup>3</sup> , George Soufras<sup>1</sup> , George Hahalis<sup>1</sup> 

To the Editor,

Aortic aneurysm is a worrisome condition, with <1 in 3 individuals with rupture surviving after surgical intervention. In the United States, 13,000 deaths are attributable to aortic aneurysm rupture annually (1). Abdominal aortic aneurysm, in particular, affects >5% of the population in developed countries. The problem will accrue over time because the pathophysiology, etiology, and pharmacotherapies for aortic aneurysm are still limited. Therefore, determining the causality, elucidating the pathophysiology, and applying appropriate preventive and therapeutic modalities seem to be of paramount importance. A very important paper recently published in the European Journal of Rheumatology included the case of a 63-year old male patient with systemic lupus erythematosus associated with aneurysm of the ascending aorta who was successfully operated; however, histological examination revealed inflammatory lesions that could lead to dissection and death (2).

These lesions comprised medial cystic degeneration, smooth muscle necrosis, and mild adventitial inflammatory cell infiltration. Numerous lymphocytes, T cells, (CD3, CD4, CD5, and CD8), B cells (L26 and CD19), monocytes/granulocytes, monocytes/macrophages KP-1 (CD68), neutrophil granulocytes, mature B cells, dendritic follicular cells, and HLA-DR (MHC class II cell surface receptor)-positive cells were also present.

These findings raise important issues that associate systemic lupus erythematosus with the pathophysiology, prevention, and treatment of aortic dissection and aortic aneurysm.

1. Recent reports have also emphasized the important role of immunoglobulin E (IgE) that activates CD4+ T cells, mast cells, and macrophages, which contribute to aortic aneurysm pathogenesis (3). Indeed, in type A aortic dissection, the number of mast cells, CD68+ macrophages, CD3+ and CD4+ T lymphocytes, and neutrophils are significantly increased (4). IgE-activated mast cells release specific proteases, such as trypsin and chymase (5). Trypsin activates thrombin receptors and the zymogen forms of metalloproteinases (MMPs), including collagenase, gelatinase, and stromelysin, and degrades fibronectin, vitronectin, and neuropeptides, thus promoting arterial dissection and thrombosis. Chymase activates MMPs, including matrix metalloproteinase (MMP)-1,-2, and -9, degrades fibronectin and thrombin, and converts angiotensin I to angiotensin II. IgEs also activate smooth muscle and endothelial cells to release cytokines and chemokines. T cells express the receptor FcεR1 that has high affinity for IgE. IgG4-related diseases are among the various causes of inflammatory abdominal aortic aneurysm, and many of these diseases are closely related to allergic and autoimmune diseases (6). Therefore, an association between aortic dissection and Kounis hypersensitivity-associated acute syndrome (7) affecting the aortic lumen cannot be excluded (Figure 1).
2. Inflammation plays an important role in the acute type A aortic dissection. Inflammation is characterized by dysregulation of MMP-tissue inhibitor of metalloproteinase (MMP-TIMP) interaction, increase in vascular endothelial growth factor A (VEGFA, a protein encoded by VEGFA expression), and increase in transforming growth factor-beta (TGF-β, a polypeptide cytokine) signaling (8). The authors of this paper have suggested further investigations to unveil mechanisms implicated in dissection and to reveal novel diagnostic biomarkers.
3. The pineal gland secretes the hormone melatonin (N-acetyl-5-methoxy tryptamine), which suppresses angiotensin II-induced human antigen R expression through the inhibition of NF-κB signaling. In



**ORCID ID of the corresponding author:**

N.G.K. 0000-0002-9751-6710;  
I.K. 0000-0002-1033-5299;  
D.V. 0000-0003-4048-740X;  
G.S. 0000-0002-6785-2107;  
G.H. 0000-0002-1483-1353.

**Cite this article as:** Kounis NG, Koniari I, Velissaris D, Soufras G, Hahalis G. Aortic aneurysm and dissection in systemic lupus erythematosus-pathophysiologic and therapeutic considerations. Eur J Rheumatol 2018; DOI: 10.5152/eurjrheum.2018.17125.

<sup>1</sup> Department of Cardiology, University of Patras Medical School, Achaia, Greece

<sup>2</sup> Department of Electrophysiology, Royal Brompton Hospital, London, United Kingdom

<sup>3</sup> Department of Internal Medicine, University of Patras Medical School, Achaia, Greece

**Address for Correspondence:**

Nicholas G. Kounis, Department of Cardiology, University of Patras Medical School, Achaia, Greece

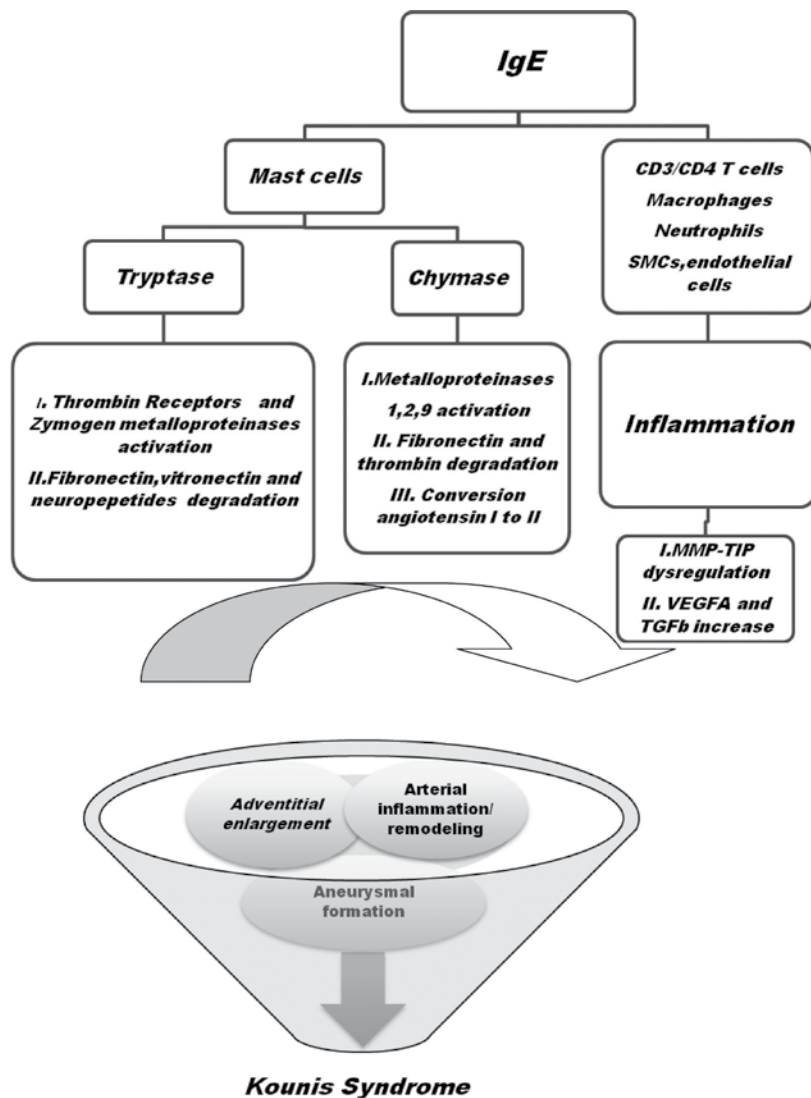
E-mail: ngkounis@otenet.gr

Submitted: 19 September 2017

Accepted: 21 December 2017

Available Online Date: April 19, 2018

©Copyright by 2018 Medical Research and Education Association - Available online at www.eurjrheumatol.org.



**Figure 1.** Kounis syndrome

ApoE<sup>-/-</sup> mice infused with angiotensin II in vivo, the administration of melatonin decreases the levels of metalloproteinase-2 and -9 and attenuates the development of abdominal aortic aneurysm (9). Gingival fibroblast cell-based therapy is also a promising approach to inhibit aneurysm progression and rupture through the local production of TIMP-1 (10).

4. An important question that arises is whether MMP activation precedes dissection or its upregulation occurs in response to the local trauma caused by dissection. Clinical evidence shows that inflammatory cell activation precedes aneurysmal dilatation. Mast cells circulate in an immature form, which then mature and release their inflammatory content after several days or weeks. Therefore, they must be present just before aortic dilatation or dissection. This is also supported by histolog-

ical examination of aortic aneurysm specimens, which shows that an inflammatory process is involved in the aneurysm wall specimens in not only inflamed but also noninflamed areas (11).

5. Various heritable syndromes are associated with thoracic aortic aneurysms, such as autosomal dominant polycystic kidney disease, Ehlers-Danlos syndrome, familial thoracic aortic aneurysms and dissections, Loeys-Dietz syndrome, Marfan syndrome, neurofibromatosis type 1, bicuspid aortic valve, and coarctation of the aorta. The last conditions are thought to be a hemodynamic consequence of valve defect. However, multiple lines of evidence currently suggest that a genetic predisposition contributes to the pathogenesis of both aortic pathologies. In a recent study, targeted resequencing of 22 candidate genes using HaloPlex target enrichment

in a strictly defined bicuspid aortic valve/thoracic aortic aneurysm cohort was performed, and it was found that the strongest candidate susceptibility gene was SMAD6. According to the study, SMAD6 gene mutations significantly contribute to the etiologies of thoracic aortic aneurysm and bicuspid aortic valve (12).

5. Systemic lupus erythematosus not only contributes to the development of a thoracic aneurysm as described by Corominas et al. (2) but also nearly increases mortality in patients suffering from myocardial infarction, stroke, or congestive heart failure compared with their age- and sex-matched controls. On searching the English language medical literature for reports on aortic aneurysms, including dissection in patients with systemic lupus erythematosus, published between January 2009 and November 2016, nine cases were identified (13).

According to a recently published case-control study which compared patients with systemic lupus erythematosus with age- and sex-matched controls, patients with systemic lupus erythematosus had up to 4.5-fold increased relative risk of developing aortic aneurysm (14). Furthermore, old age, male sex, hypertension, disease duration of >3 years, and prolonged corticosteroid treatment constituted additional factors responsible for the development of aortic aneurysm and/or aortic dissection (15).

Therefore, prompt diagnosis and treatment of this disease could prevent the evolution of aortic aneurysm and progression of other cardiovascular diseases (16).

All above clinical associations along with biochemical and immunological processes induce the loss of aortic wall integrity and facilitate adventitial enlargement that leads to aortic lumen aneurysmal formation and/or dissection. Therefore, taken together, these findings suggest that determining underlined autoimmune diseases, such as systemic lupus erythematosus, inhibiting inflammatory mediators released from inflammatory cells, and/or neutralizing the action of MMPs could be promising modes for the inhibition of aortic aneurysm growth and dissection.

## REFERENCES

1. Kim HW, Stansfield BK. Genetic and Epigenetic Regulation of Aortic Aneurysms. *Biomed Res Int* 2017; 2017: 7268521.
2. Corominas H, Tsokos M, Quezado M, Tsokos GC. Aneurysm of the ascending aorta in systemic

- lupus erythematosus: Case report and review of the literature. *Eur J Rheumatol* 2017; 4: 133-5. [\[CrossRef\]](#)
3. Wang J, Lindholt JS, Sukhova GK, Shi MA, Xia M, Chen H, et al. IgE actions on CD4+ T cells, mast cells, and macrophages participate in the pathogenesis of experimental abdominal aortic aneurysms. *EMBO Mol Med* 2014; 6: 952-69. [\[CrossRef\]](#)
  4. Wu D, Choi JC, Sameri A, Minard CG, Coselli JS, Shen YH, et al. Inflammatory Cell Infiltrates in Acute and Chronic Thoracic Aortic Dissection. *Aorta (Stamford)* 2013; 1: 259-67. [\[CrossRef\]](#)
  5. Wang Y, Shi GP. Mast cell chymase and tryptase in abdominal aortic aneurysm formation. *Trends Cardiovasc Med* 2012; 22: 150-5. [\[CrossRef\]](#)
  6. Jun H, Jung CW. Immunoglobulin G4-Related Inflammatory Abdominal Aortic Aneurysm Associated with Myasthenia Gravis, With Contained Rupture. *Vasc Endovascular Surg* 2016; 50: 571-4. [\[CrossRef\]](#)
  7. Kounis NG. Kounis syndrome: an update on epidemiology, pathogenesis, diagnosis and therapeutic management. *Clin Chem Lab Med* 2016; 54: 1545-59. [\[CrossRef\]](#)
  8. Kimura N, Futamura K, Arakawa M, Okada N, Emrich F, Okamura H, et al. Gene expression profiling of acute type A aortic dissection combined with in vitro assessment. *Eur J Cardiothorac Surg* 2017; 52: 810-7. [\[CrossRef\]](#)
  9. Kong J, Zhang Y, Liu S, Li H, Liu S, Wang J, et al. Melatonin attenuates angiotensin II-induced abdominal aortic aneurysm through the down-regulation of matrix metalloproteinases. *Oncotarget* 2017; 8: 14283-93. [\[CrossRef\]](#)
  10. Giraud A, Zeboudj L, Vandestienne M, Joffre J, Esposito B, Potteaux S, et al. Gingival fibroblasts protect against experimental abdominal aortic aneurysm development and rupture through TIMP-1 production. *Cardiovasc Res* 2017; 113: 1364-75. [\[CrossRef\]](#)
  11. Rose AG, Dent DM. Inflammatory variant of abdominal aortic atherosclerotic aneurysm. *Arch Pathol Lab Med* 1981; 105: 409-13.
  12. Gillis E, Kumar AA, Luyckx I, Preuss C, Cannaeerts E, van de Beek G, et al. Candidate Gene Resequencing in a Large Bicuspid Aortic Valve-Associated Thoracic Aortic Aneurysm Cohort: SMAD6 as an Important Contributor. *Front Physiol* 2017; 8: 400-10. [\[CrossRef\]](#)
  13. Silvestri V, Simonte G. Aortic Pathology in Systemic Lupus Erythematosus: A Case Report and Review of Literature. *Ann Vasc Surg* 2017; 43: 312.e5-12. [\[CrossRef\]](#)
  14. Guy A, Tiosano S, Comaneshter D, Tekes-Manova D, Shovman O, Cohen AD, et al. Aortic aneurysm association with SLE - a case-control study. *Lupus* 2016; 25: 959-63. [\[CrossRef\]](#)
  15. Wang SH, Chang YS, Liu CJ, Lai CC, Chen TJ, Chen WS. Incidence and risk analysis of aortic aneurysm and aortic dissection among patients with systemic lupus erythematosus: a nationwide population-based study in Taiwan. *Lupus* 2014; 23: 665-71. [\[CrossRef\]](#)
  16. Kounis NG. Inflammation, systemic lupus erythematosus and the Kounis mast cell activation-associated syndrome. *Rev Port Cardiol* 2015; 34: 369-70. [\[CrossRef\]](#)